UNIVERSIDADE MOGI DAS CRUZES

CRISTIANE BARROS ANDRÉ

USO DO PLANEJAMENTO TRIDIMENSIONAL NA PREVISIBILIDADE DOS TRATAMENTOS DE EXPANSÃO RÁPIDA DA MAXILA ASSISTIDA POR MINI-IMPLANTES (MARPE)

Mogi das Cruzes

2024

CRISTIANE BARROS ANDRÉ

USO DO PLANEJAMENTO TRIDIMENSIONAL NA PREVISIBILIDADE DOS TRATAMENTOS DE EXPANSÃO RÁPIDA DA MAXILA ASSISTIDA POR MINI-IMPLANTES (MARPE)

Tese apresentada ao curso de Engenharia Biomédica da Universidade Mogi das Cruzes, para obtenção do grau de Doutor.
Orientador: Prof. Dr. Fábio Dupart Nascimento

Mogi das Cruzes

2024

Ficha catalográfica
Universidade de Mogi das Cruzes - Biblioteca Central

André, Cristiane Barros
A555u Uso do planejamento tridimensional na previsibilidade dos tratamentos de expansão rápida da maxila assistida por mini implantes / Cristiane Barros André. -- Mogi das Cruzes, SP: Universidade de Mogi das Cruzes, 2024.
121 f. : il.

Tese (Doutorado em Engenharia Biomédica) -- Universidade de Mogi das Cruzes, 2024.
Orientação: Profa. Dr. Fabio Dupart Nascimento.
Inclui bibliografia.

1. Técnica de expansão palatina 2. Cirurgia bucal 3. Tomografia computadorizada de feixe 4. Maxila I. Nascimento, Fabio Dupart II.Universidade de Mogi das Cruzes III. Título

CDD 610.28

Elaborada por Maria Cristina Alves Silva Xavier – CRB-8/10077

UMC
UNIVERSIDADE

Tel.: (11) 4798-7000
0800 19 2001
www.umc.br

Fls. 008-Livro II DR

ATAS

ATA DA SESSÃO PÚBLICA DE DEFESA DE TESE DE DOUTORADO EM ENGENHARIA BIOMÉDICA DA UNIVERSIDADE DE MOGI DAS CRUZES

Às oito horas do dia um de julho de dois mil e vinte e quatro, pela Universidade de Mogi das Cruzes, realizou-se a defesa da tese intitulada "USO DO PLANEJAMENTO TRIDIMENSIONAL NA PREVISIBILIDADE DOS TRATAMENTOS DE EXPANSÃO RÁPIDA DA MAXILA ASSISTIDA POR MINI-IMPLANTES (MARPE)". para obtenção do grau de doutor(a) pelo(a) candidato(a) **Cristiane Barros André.** Tendo sido o número de créditos alcançados pelo(a) mesmo(a) no total de 78 (setenta e oito), a saber: 42 unidades de crédito em disciplinas e atividades na pós-graduação e 36 unidades de crédito no preparo da tese, o(a) aluno(a) perfaz assim os requisitos para obtenção do grau de doutor(a). A comissão examinadora foi constituída pelos senhores professores doutores: Fábio Dupart Nascimento, da Universidade Federal de São Paulo, Elis Andrade de Lima Zutin, e Tatiana Ribeiro de Campos Mello, da Universidade de Mogi das Cruzes, e Maurício de Almeida Cardoso, do Centro de Pesquisas Odontológicas São Leopoldo Mandic, e Silvia Amélia Scudeler Vedovello, da Universidade Estadual de Campinas, sob a presidência do primeiro como orientador do(a) aluno(a). A sessão pública da defesa da tese foi aberta pelo senhor presidente da comissão que apresentou o(a) candidato(a). Em seguida o(a) candidato(a) realizou uma apresentação oral de seu trabalho, ao final da qual seguiram-se as arguições pelos membros da comissão examinadora. A seguir, a comissão, em sessão secreta, conforme julgamento discriminado por cada membro, considerou o(a) candidato(a)

APROVADA (aprovado(a) /reprovado(a)) por UNANIMIDADE (unanimidade/maioria)

Mogi das Cruzes, 01 de julho de 2024.

Comissão Examinadora	Julgamento
Prof. Dr. Maurício de Almeida Cardoso	aprovado (aprovado(a)/reprovado(a))
Profª Drª Silvia Amélia Scudeler Vedovello	aprovada (aprovado(a)/reprovado(a))
Profª Drª Elis Andrade de Lima Zutin	Aprovada (aprovado(a)/reprovado(a))
Profª Drª Tatiana Ribeiro de Campos Mello	aprovada (aprovado(a)/reprovado(a))
Prof. Dr. Fábio Dupart Nascimento	Aprovada (aprovado(a)/reprovado(a))

gov.br Documento assinado digitalmente ELIS ANDRADE DE LIMA ZUTIN Data: 01/07/2024 18:31:55-0300 Verifique em https://validar.iti.gov.br

RESUMO

Objetivo: Apresentar aspectos sobre o diagnóstico por imagem, planejamento digital, variações anatômicas e diferentes possibilidades de *design* de MARPE. **Material e métodos:** exames de tomografias foram avaliados com os seguintes critérios de inclusão**:** arquivos de tomografia computadorizada de feixe cônico da região da maxila do banco de dados do setor de planejamento digital da indústria de ortopedia facial customizada Kika Digital Orthodontics, faixa etária entre 9 e 53 anos, presença de deficiência transversal da maxila. O presente trabalho foi dividido em 4 artigos, sendo eles: anatomia craniofacial; cirurgia virtual; *design* do aparelho; e processos de fragilização das suturas da face. **Resultados:** a sutura palatina mediana apresentou a classificação D (34%) como a mais comum, e a "A" foi a menos frequente (7.5%). A prevalência de pacientes com aumento do tamanho do forame nasopalatino foi de 46%, enquanto a presença de tórus palatino foi de 23%. O planejamento digital possibilita um posicionamento que evite a colisão com o tecido mole lateral do palato, além de um posicionamento bicortical de cada mini-implante. Sobre os diferentes desenhos de MARPE, em 90% dos casos, os dentes 16 e 26 foram utilizados como suporte, e o parafuso expansor mais usado foi o de 13 mm (64.1% dos casos). Uma espessura óssea maior foi observada em homens (10.1 ± 2.1 mm) na região paramediana. Acerca das corticoperfurações guiadas, observou-se na sutura palatina mediana uma média de 5.68 ± 1.31 perfurações, e a distância entre elas foi de 2.03 ± 0.5 mm. **Conclusão**: A associação do planejamento digital, modelagem computacional, conhecimento anatômico, e design customizado do dispositivo, é essencial para potencializar as chances de sucesso da técnica MARPE, aumentando as possibilidades e resoluções dentro da área de engenharia de reabilitação.

Palavras-chave: técnica de expansão palatina; tomografia computadorizada de feixe cônico; procedimentos de ancoragem ortodôntica; desenho de aparelho ortodôntico.

ABSTRACT

Objective: to present aspects of diagnosis, digital planning, anatomical variations and different MARPE design possibilities. **Material and methods**: computed tomography scans (CT scans) were evaluated using the following inclusion criteria: CT scans of the maxillary region, age range between 9 and 53 years, presence of a transverse maxillary deficiency. This study was divided into 4 articles: craniofacial anatomy; virtual surgery; appliance design; and facial suture weakening processes. **Results:** The midpalatal suture was most classified as D (34%), and “A” was the least frequent (7.5%). The prevalence of patients with an increase in the size of the nasopalatine foramen was 46% and the presence of a palatine torus was 23%. Digital planning allows digital positioning that avoids collision with the lateral soft tissue of the palate, as well as bicortical positioning of each mini-implant. Regarding the different MARPE designs, in 90% of the cases, teeth 16 and 26 were used as supports, and the most used expander screw was the 13 mm (64.1% of the cases). A greater bone thickness was observed in men (10.1 ± 2.1 mm) in the paramedian region. Regarding the guided corticopuncture, a mean of 5.68 ± 1.31 perforations was observed in the midpalatal suture, and the distance between them was 2.03 ± 0.5 mm. **Conclusion**: The combination of digital planning, computer modeling, anatomical knowledge and customized device design is essential to enhance the chances of success of the MARPE technique, increasing the possibilities and resolutions within the field of rehabilitation engineering.

Keywords: palatal expansion technique; cone beam computed tomography; orthodontic anchorage procedures; orthodontic appliance design.

LISTA DE ABREVIATURAS E SIGLAS

3D	Tridimensional
cm	Centímetros
CAD	*Computer aided design*
CBCT	*Cone Beam Computed Tomography*
CT	*Computed Tomography*
DAT	Dispositivo de ancoragem temporária
DICOM	*Digital Imaging Standard and Communications in Medicine* (Extensão do arquivo da tomografia)
Dp	Desvio padrão
ERM	Expansão rápida da maxila
ERMAC	Expansão rápida da maxila assistida cirurgicamente
FOV	Área da tomografia
Kvp	Quiilovoltagem
mA	Miliamperagem
MARPE	Mini-implant assisted rapid palatal expansion (Expansão maxilar assistida por mini-implantes)
MARPE EX	Dispositivo de MARPE com anéis com altura ajustável
mm	Milímetros
n	Tamanho da amostra
RME	Rapid maxillary expansion
Sd	*Standard deviation*
Se	*Standard error*
STL	*Standard Triangle Language* (extensão do arquivo obtido no escaneamento intraoral)
SARPE	Surgically assisted rapid palatal expansion
TCFC	Tomografia computadorizada de feixe cônico

SUMÁRIO

1 INTRODUÇÃO 8

2 PROPOSIÇÃO 18

3 MATERIAL E MÉTODOS 19

4 DESENVOLVIMENTO 21

4.1 Objetivos gerais do trabalho 21

4.2 Status das publicações 22

4.3 Artigos 23

4.3.1 Parameters for mini-implant supported rapid maxillary expansion: prevalence of nasomaxillary anatomical variations 23

4.3.2 Surgical Digitally Guided Planning for the Mini-Screw Assisted Rapid 43

Palatal Expansion (MARPE) and Suture Perforation: MARPE Guide 43

4.3.3 Miniscrew-assisted rapid palatal expansion (MARPE): factors influencing planning 63

4.3.4 Guided corticopuncture associated with microimplant-assisted rapid palatal expansion (MARPE): planning variables 92

5 DISCUSSÃO 106

6 CONCLUSÕES 113

REFERÊNCIAS 115

1 INTRODUÇÃO

O tratamento de escolha para pacientes portadores de deficiência transversal da maxila e mordida cruzada posterior esquelética é a expansão rápida da maxila (ERM). Este tratamento deve ser realizado o mais cedo possível, pois, caso estas características sejam mantidas podem ocorrer desvios no crescimento facial que resultam em comprometimento estético e funcional do indivíduo (PROFFIT; FIELDS; SARVER, 2007).

Os primeiros registros da ERM ocorreram em 1860 por Angel. Contudo, somente no ano de 1965 este procedimento foi difundido entre os ortodontistas, quando Haas obteve resultados promissores com a técnica. Em seguida, outros estudos clínicos foram realizados e o procedimento foi considerado seguro e eficaz (WERTZ, 1970; HAAS, 1965; HAAS,1980). A literatura ainda relata outros benefícios obtidos com a ERM, a saber: a redução da obstrução nasal, aumento transversal das cavidades nasais, aumento da largura maxilar, redução da resistência nasal e aumento da capacidade intranasal, como melhoria do padrão respiratório (ZHAO *et al*., 2010, IWASAKI *et al*., 2014; BUCK *et al*., 2016).

Porém, alguns efeitos colaterais foram observados após a realização da ERM, como: inclinação vestibular dos dentes posteriores, reabsorção das raízes e recessão gengival (ODENRICK *et al*., 1991; ERVERDI *et al*., 1994; GARIB *et al*., 2005; BAYSAL *et al*., 2012; DINDAROĞLU; DOĞAN, 2012). Estes efeitos colaterais se intensificam conforme a idade e maturação esquelética avançam, por isso a importância de se realizar a correção o mais cedo possível.

Pacientes que não tratam a deficiência maxilar transversal durante a fase de crescimento, devem realizar o tratamento cirúrgico, chamado de expansão rápida da maxila cirurgicamente assistida (ERMAC), que se trata de um procedimento de alto custo. Uma opção menos invasiva em relação à ERMAC, é a utilização de dispositivos de ancoragem temporária (DATs) associados à ERM, a qual obtemos uma expansão ortopédica com poucos efeitos colaterais (CELENK-KOCA *et al*., 2018; CHOI *et al*.; 2023; LIU *et al*., 2023). Normalmente, este procedimento é bem aceito pelos pacientes, por ser menos invasivo e ter um baixo custo quando comparado à ERMAC

(ANDRÉ *et al*., 2021). A expansão rápida da maxila apoiada em DATs pode ser classificada em duas categorias: pacientes em crescimento e pacientes com crescimento finalizado.

O protocolo para tratar pacientes em crescimento se baseia na utilização de um dispositivo que possui apoio esquelético na região anterior da maxila e foi criado em 2008 por Wilmes *et al*., denominado de Hyrax híbrido. O Hyrax híbrido foi idealizado com o objetivo de minimizar os efeitos colaterais dentários da ERM e aumentar os efeitos esqueléticos (Wilmes *et al*., 2010). Este dispositivo possui apoio híbrido (dento-esquelético), sendo o apoio esquelético constituído por 2 DATs na região anterior da maxila e o apoio dentário realizado por meio de bandas nos dentes 16 e 26. Os estudos têm demonstrado algumas vantagens deste dispositivo em relação aos dispositivos convencionais (dentossuportados ou dento-muco-suportados), tais como menor inclinação vestibular e redução da cortical vestibular nos dentes posteriores, maiores efeitos esqueléticos nasomaxilares e melhor resolução da obstrução nasal (WILMES *et al*, 2010; CHEUNG *et al* 2020; PASQUA *et al*, 2021). Além disso, o Hyrax híbrido pode ser indicado quando há falta de apoio dentário na maxila (perda precoce dos molares decíduos), ampliando as possibilidades de tratamento nestes casos.

Para pacientes adultos, a expansão maxilar apoiada sobre DATs é conhecida como Mini-implant assisted rapid palatal expansion (MARPE). Nesta técnica a ERM também é realizada com um apoio dento-esquelético, mas com 4 ou 6 DATs (LEE *et al*, 2010; CURY *et al* 2019). O apoio dentário normalmente é feito pelos dentes 16 e 26, porém muitos pacientes adultos são mutilados ou apresentam perdas ósseas, principalmente na região vestibular, o que faz com que os dentes de apoio sejam alterados (ANDRÉ, 2023). Estudos clínicos demonstraram que o MARPE é eficiente, pois também possibilita a separação inclusive das suturas posteriores do processo pterigoide (LI *et al*, 2020). Além disso, foi observado por André *et al.* (2021) que as tensões do MARPE EX podem se distribuir até a lâmina lateral do processo pterigoide, que é uma das regiões de maior resistência (BRUNETTO *et al*, 2017), promovendo o sucesso da técnica mesmo em pacientes com estágio de maturação mais avançado da sutura palatina mediana.

Além da melhora na oclusão dentária e na estética facial, o paciente também pode experimentar melhorias na função respiratória e na qualidade do sono

(BRUNETTO *et al*., 2022; JARA *et al*., 2023). Entretanto, é fundamental que o paciente siga as orientações do ortodontista e compareça às consultas de acompanhamento para garantir a eficácia do tratamento e prevenir complicações. Além disso, o paciente deve estar atento às recomendações do profissional de saúde no que diz respeito à higienização do aparelho MARPE e da cavidade bucal, a fim de minimizar o risco de infecções e garantir a saúde dos dentes e gengiva (ANDRÉ *et al*., 2021; ANDRÉ, 2022). Essa prática também ajuda a prevenir a formação de tártaro e placa bacteriana, contribuindo para a manutenção da saúde bucal em longo prazo. O tratamento com MARPE deve ser visto como uma abordagem colaborativa entre o paciente e o profissional de saúde, que trabalham em conjunto para alcançar os melhores resultados possíveis (BRUNETTO *et al*., 2016. A comunicação aberta e a disposição para compartilhar preocupações e dificuldades são essenciais para o sucesso do tratamento e a satisfação do paciente.

Tanto o MARPE quanto o Hyrax híbrido são bem aceitos pelos pacientes, são menos invasivos, e têm um custo menor quando comparados à expansão rápida da maxila cirurgicamente assistida (WILMES *et al*., 2010; CHOI *et al*., 2016; GUNYUZ *et al*., 2015, PASQUA *et al*., 2021; INCHINGOLO *et al*., 2022). Resultados promissores foram observados com a realização desta técnica, tais como: sucesso da abertura da sutura palatina mediana de 86,96% dos casos, ganho esquelético transversal da maxila significativo em pacientes com idade acima dos 20 anos (CHOI *et al*., 2016); separação de suturas posteriores tais como a sutura pterigopalatina, em pacientes com mais de 18 anos (COLAK *et al*., 2020; KAPETANOVIĆ *et al*., 2022); estabilidade dos resultados da ERM um ano após a finalização da expansão em pacientes com mais de 20 anos de idade (LIM *et al*., 2017); expansão ortopédica da maxila com poucos efeitos colaterais (NAVEDA *et al*., 2023); tendência a uma abertura mais paralela e expansão mais pronunciada da cavidade nasal (CELENK-KOCA *et al*., 2018; ZONG *et al*., 2019); aumento significativo de volume aéreo e melhoria da constrição respiratória em pacientes com mais de 17 anos (STORTO *et al*., 2019); efeitos ortopédicos mais satisfatórios comparando-se com a cirurgia de expansão, com um padrão mais paralelo de abertura da sutura com MARPE; efeitos na cavidade nasal foram mais pronunciados com a técnica MARPE (JESUS *et al*., 2021).

Embora tenhamos evidências científicas favoráveis sobre a expansão da maxila apoiada em DATs, nos deparamos com alguns casos de insucesso, advindos de diversos fatores anatômicos, e relacionados à idade, maturação esquelética e sexo (JESUS *et al*., 2021; OLIVEIRA *et al*., 2021; MEIRELLES *et al*., 2023, JEON *et al*., 2021). Por isso, foram criados protocolos de MARPE a fim de ampliar as possibilidades ortodônticas. Com todos esses desafios, a técnica MARPE por pouco tempo foi realizada de forma analógica, sem o uso da tomografia e do escaneamento intraoral para o planejamento.

As primeiras tentativas de planejamento se baseavam em medidas de espessura de osso, mucosa e referências de posicionamento dentário (NOJIMA *et al*., 2018). Por meio do arquivo no formato *Digital Imaging and Communications in Medicine* (DICOM) realizava-se a análise da maturação das suturas faciais e algumas mensurações de espessura óssea. Para a sutura palatina mediana, a análise realizada segue o método proposto por Angelieri *et al*., 2013, no qual o operador deve ser calibrado para executar a técnica com reprodutibilidade (BARBOSA *et al*., 2019). Esta técnica é importante como método auxiliar de diagnóstico, pois traz informações quanto à possível dificuldade e resistência à separação da sutura palatina mediana de acordo com seu estágio de maturação. Além disso é possível realizar também a classificação de outra sutura envolvida na ERM, a sutura zigomaticomaxilar (ANGELIERI *et al*., 2017). A avaliação de ambas as suturas é realizada por meio do acesso aos cortes sagitais e axiais da tomografia, e a sutura é avaliada em um estágio de “A a E”, sendo “A” o estágio mais inicial de maturação e “E” o estágio mais avançado.

A sutura pterigopalatina também é avaliada, mesmo não tendo uma classificação consolidada na literatura. Quando está em estágio avançado de maturação, esta sutura apresenta uma característica bastante homogênea comparada aos tecidos ósseos vizinhos, sendo um alerta ao ortodontista pois isto sugere maior resistência à ERM. Na sequência a sutura transpalatina é analisada quanto à sua localização e forma. Além do estágio de maturação, é muito importante verificar a forma, aspecto e direções destas suturas, pois elas podem ser retilíneas, sinuosas, contínuas, ou ainda curvilíneas. Isto pode ocorrer tanto no sentido horizontal, quanto vertical observadas no corte coronal, sagital e axial (ANDRÉ, 2018).

Variações anatômicas são comuns e devem ser observadas minuciosamente no planejamento das expansões maxilares apoiadas em DATs, como por exemplo: desvio do septo nasal, extensão alveolar do seio maxilar, dentes impactados, tórus maxilar, profundidade do palato, formato e dimensão anteroposterior e transversal da maxila. Um exemplo claro disto é o palato em forma de V na região anterior (ANDRÉ *et al*., 2021). Por meio da análise de exames de imagens, as variações anatômicas são encontradas com frequência, como os *mesiodens*, lesões endodônticas, dentes inclusos, falhas e perdas ósseas.

Estas avaliações anatômicas e mensurações tomográficas foram tentativas que apresentaram informações importantes (ANDRÉ, 2018; ANDRÉ *et al*., 2021). Entretanto, esta tomografia era enviada em forma de imagem pelos centros radiológicos, o que não permitia planejar tridimensionalmente a abordagem terapêutica. Com isso não era possível construir um guia que transcrevesse essas medidas ao paciente. E estas medidas não reproduziam a localização e direção tridimensional dos DATs, tornando a construção do aparelho era empírica, não sendo capaz de reproduzir a trajetória exata dos DATs do MARPE, por não terem a capacidade de serem reproduzidas tridimensionalmente.

Para suprir essa necessidade do perfeito posicionamento tridimensional, foram criados guias de posicionamento digital, que são utilizados para reproduzir em boca o planejamento 3D (MAINO *et al*., 2016; DEGABRIELE *et al*., 2017; ANDRÉ, 2019; LOMBARDO *et al*., 2019; CANTERELLA *et al*., 2020, LO GIUDICE et al., 2020, ANDRÉ *et al*., 2021). Desta forma, para agregar segurança e precisão aos procedimentos, aliados à tendência digital na Ortodontia, utiliza-se a tecnologia para realizar a cirurgia virtual de instalação dos DATs e do próprio torno expansor, de forma elimando quaisquer fatores que causem o insucesso da técnica. Este guia, denominado MARPE *Guide* (ANDRÉ. 2019; ANDRÉ, 2020; PASQUA e CARDOSO, 2021, ANDRÉ *et al*., 2021), é nada mais que um guia criado em 3D sobre o modelo digital (STL) do próprio paciente (ANDRÉ, 2019; ANDRÉ, 2020), com a finalidade de reproduzir fielmente o planejamento 3D.

Esta instalação virtual é realizada após a sobreposição do arquivo da tomografia computadorizada de feixe cônico (TCFC – arquivo no formato DICOM) com o arquivo do escaneamento intraoral (STL), onde é possível avaliar de forma individual

e tridimensional as estruturas do complexo nasomaxilar. Dessa forma, é possível escolher com precisão o local para o posicionamento dos DATs de forma segura, assim como o correto posicionamento do torno expansor, que é realizado a partir do posicionamento natural da cabeça, seguindo o protocolo porpost de Pasqua *et al*., 2021. Isto garante um correto posicionamento, eliminando o risco do torno de expansão ser adaptado ao modelo de forma inclinada, causando uma assimetria facial. Desta forma, reduzimos chances de insucesso com o uso desta tecnologia aplicada aos exames 3D do paciente, pois é possível selecionar o tamanho de cada DAT e sua sobra de rosca (LI *et al*., 2020; LEE *et al*., 2021), e ainda prever com acurácia a trajetória destes DATs, devido ao design do aparelho criado durante a cirurgia virtual. Assim, evitamos lesionar estruturas anatômicas importantes, mesmo nos casos mais complexos de variações anatômicas.

As cirurgias virtuais são seguras, fiéis e reprodutíveis, pois permitem uma avaliação anatômica completa da região do complexo nasomaxilar, local onde os DATs são instalados, realizando as fragilizações das suturas e criando o design dos aparelhos. Os desafios da bicorticalidade dos DATs, a busca por regiões ósseas com espessura adequada para suportar as forças exercidas durante a expansão maxilar, definir as dimensões exatas dos DATs de forma individualizada, além dos desafios anatômicos de cada indivíduo, os quais na ERM convencional não eram avaliados, por não se ter a inserção de mini-implantes em osso, sendo todo o suporte dentário ou dentomucossuportado (André *et al*., 2021).

Estudos sobre variações anatômicas que podem estar relacionadas diretamente ao sucesso ou insucesso da técnica ainda são escassos (ANDRÉ, 2020; ANDRÉ, 2021, ANDRÉ *et al*., 2021; JEON *et al*., 2021). Algumas variações anatômicas determinam o desenho do aparelho, o sítio de instalação dos DATs, a altura do expansor e a necessidade de fragilização das suturas envolvidas no processo.

Em alguns casos, se estas variações não forem identificadas previamente, existe o risco da inserção dos DATs, por exemplo, em locais com pouco volume ósseo, muito volume de tecido mole, ou sobre estruturas importantes como septo nasal, seio maxilar, forame nasopalatino, artéria palatina maior ou sobre as suturas da maxila (ANDRÉ, 2019; ANDRÉ, 2020).

Por isso o design do aparelho e a instalação virtual guiada são decisivos para o sucesso do tratamento, uma vez que o design pode sofrer alterações de acordo com as características individuais de cada paciente. A técnica guiada de instalação nos permite criar aparelhos segmentados, que são confeccionados em partes, o que dificulta a manufatura e aumenta o tempo de confecção do aparelho, mas garante um dispositivo que não lesione estruturas importantes e que seu design favoreça a melhor biomecânica para cada caso. As partes segmentadas do aparelho são o torno expansor e os anéis dos DATs que se encontram em modelos diferentes desenvolvidos pensando nas variações anatômicas e na estabilidade do aparelho em relação ao osso e ao tecido mole, e estes em boca reproduzem o planejamento digital e ainda são responsáveis por guiar os DATs (ANDRÉ, 2020; ANDRÉ *et al*., 2021).

Esta versatilidade torna possível a adição de mais DATs ao MARPE convencional, como nos casos de espessura óssea reduzida, onde novos anéis são soldados a laser ao corpo deste MARPE convencional (CURY *et al*., 2019). Porém, quanto mais nos aprofundamos nas avaliações anatômicas, mais observamos a necessidade de novos recursos. Sendo um deles a utilização de DATs na região do processo alveolar.

Para possibilitar este novo conceito de MARPE, a empresa PecLab (Belo Horizonte – Brasil) desenvolveu o anel esquelético, que conta com uma tampa rosqueada, que trava o anel ao DAT (ANDRÉ, 2023). Este travamento impede que o dispositivo lesione os tecidos moles, o que causa inflamação e uma possível perda dos DATs, inclusive para movimentos anteroposteriores como a protração da maxila, a distalização de molares, associados ao MARPE ou mesmo os movimentos laterais de expansão com os mini-implantes em processo alveolar.

Com os anéis esqueléticos é possível obter o desenho de uma biomecânica realmente eficiente para cada caso, assim como um posicionamento tricortical dos DATs, aumentando a ancoragem, e consequentemente aumentando as chances de sucesso da terapia (ANDRÉ, 2023). Desta forma, ampliou-se as possibilidades de tratamento com a técnica MARPE, incluindo pacientes mutilados e com perda de volume ósseo na região parassutural, que agora podem ser tratados de forma segura.

Um fator que causa muito insucesso nas terapias de expansão da maxila associada aos DATs, são as inflamações decorrentes dos aparelhos utilizados, que comprimirem a mucosa ou impedem a correta higienização bucal no local de inserção dos DATs, causando inflamação, muitas vezes perda dos DATs ou perda de volume óssea na região circunvizinha aos DATs. Isto pode causar o insucesso da técnica devido à instabilidade que a perda óssea causa ao DATs, onde os mesmos podem inclinar ou se desadaptar. Com o uso do anel esquelético no design do MARPE customizado, o sistema de tampa e rosca mantém o aparelho a uma distância adequada da mucosa, abrindo um leque de opções de inserção de DATs, que antes não eram possíveis e ampliando as chances de sucesso, como os mini-implantes em processo alveolar. Neste caso, a força se expressa no sentido horizontal e o anel trava o DAT ao aparelho, ou seja, sem a utilização do anel esquelético, o dispositivo comprime a mucosa, causando a inflamação (ANDRÉ, 2023).

Mesmo com o planejamento virtual e todas as possibilidades de *design* associado ao MARPE (ANDRÉ, 2020; ANDRÉ *et al*., 2021), existem casos complexos de variação da espessura da maxila onde a resistência à abertura das suturas é maior, além de fatores como: idade avançada, casos de maturação avançada da sutura palatina mediana, variações anatômicas como a presença de tórus palatino e tamanho da maxila aumentado no sentido sagital (ANDRÉ *et al*., 2021). Dessa forma, Suzuki *et al*., 2018 propuseram a realização de corticoperfurações na região da sutura palatina mediana previamente à ERM, com o objetivo de reduzir a resistência durante a expansão por meio da fragilização da sutura palatina mediana.

Embora os resultados das corticoperfurações sejam favoráveis (BUD *et al*., 2021; MEIRELLES *et al*., 2023) não se trata de um procedimento preciso, uma vez que a referência anatômica para realização da perfuração é a rafe palatina (tecido mole), que nem sempre coincide com a sutura palatina mediana propriamente dita. Além disso, as brocas são utilizadas de forma empírica sem um controle vertical, resultando em perfurações insuficientes, ou, nos casos de pacientes com osso palatino com espessura reduzida, uma perfuração excessiva, atingido o septo nasal. Isto pode causar dor ao paciente, comunicação buconasal, podendo resultar em sinusite ou, em casos mais severos, pode se agravar para uma necrose óssea ou osteomielite (ANDRÉ *et al*., 2021). A técnica direta também falha quando a perfuração

é realizada muito próxima a área de instalação dos DATs, podendo criar uma zona de fragilização em regiões onde grande aporte ósseo é necessário (ANDRÉ *et al*., 2021).

Com o objetivo de proporcionar segurança e eficácia, André *et al* (2021) criaram a perfuração virtualmente guiada. Por meio da sobreposição do arquivo do escaneamento digital intraoral (STL) e da TCFC (DICOM), é possível escolher com precisão e segurança o local correto para cada perfuração, sejam as suturas sinuosas, retilíneas ou curvas (ANDRÉ, 2022). Após o planejamento das perfurações é criado um guia que reproduz o planejamento virtual, mantendo cada perfuração com sua direção e inclinação, e possui um stop para limitar a inserção da broca, a fim de não ultrapassar o limite vertical, inserindo acidentalmente no septo nasal. Este guia foi denominado Córtex *Guide* (ANDRÉ, 2022). O planejamento das corticoperfurações é realizado juntamente com o MARPE *Guide*, a fim de não realizar a corticoperfuração próxima aos DATs (ANDRÉ, 2022), garantindo uma quantidade de osso suficiente nas regiões circunvizinhas aos DATs. Com o advento da técnica guiada, as perfurações das suturas se tornaram um procedimento comum, e são muito importantes na região posterior, pois estas regiões apresentam resistência durante a ERM (ANDRÉ *et al*., 2021; ANDRÉ, 2022) assim como na região anterior (sutura intermaxilar), pois se trata de uma região com espessura óssea pronunciada (WILMES *et al*., 2016; ANDRÉ, 2021, ANDRÉ, 2023).

Vale lembrar que a técnica de expansão rápida da maxila apoiada em DATs (MARPE e Hyrax híbrido) é recente. Apesar das evoluções significativas do planejamento digital e das ferramentas que aumentam as chances de sucesso dos casos, muitas dúvidas ainda permanecem, o que demandam estudos com o objetivo de aumentar a previsibilidade destes tratamentos e garantir segurança aos pacientes. Dessa forma, o presente trabalho se propõe a apresentar aspectos importantes sobre diagnóstico, planejamento digital, diferentes possibilidades de *designs* de MARPE e ferramentas como a corticoperfuração guiada. Sendo assim, dividimos o presente trabalho em 4 tópicos importantes (artigos), sendo eles: a necessidade do conhecimento da anatomia do paciente e suas possíveis variações (avaliação detalhada da tomografia); a cirurgia virtual, que torna possível uma avaliação anatômica completa da região do complexo nasomaxilar (sobreposição da tomografia com o escaneamento intraoral); o *design* do aparelho frente a influência de variações

anatômicas; e os processos de fragilização das suturas da face, que também utilizam a sobreposição da tomografia com o escaneamento intraoral e são clinicamente executadas na mesma consulta que a instalação do aparelho expansor.

Os artigos que serão anexados em seguida têm o objetivo de apresentar a técnica de planejamento tridimensional e, com ele, compreender as variáveis que definem o planejamento de MARPE e Hyrax Híbrido. Essas variáveis expostas são do levantamento da prevalência das variações anatômicas na região nasomaxilar e da análise dos planejamentos das corticoperfurações das suturas envolvidas, para compreender as variáveis que definem o planejamento, assim como os fatores que o limitam.

Este levantamento foi realizado por meio de um banco de dados de exames de tomografias e de arquivos de escaneamento intraorais, onde são apresentados dados de uma série de instalações virtuais de DATs e corticoperfurações em regiões adequadas, uma rica discussão sobre os fatores que influenciam a modificação do design do aparelho MARPE, com o objetivo de compreender a influência destas variáveis no *design* do aparelho.

A apresentação será feita por meio de 4 artigos completos, sendo 2 já publicados, e 2 em processo de revisão.

2 PROPOSIÇÃO

O presente trabalho se propõe a realizar um amplo levantamento das variações anatômicas que podem causar o insucesso na técnica MARPE, desde de indivíduos mais jovens até os mais maduros. Além disso, foram apresentados os protocolos de avaliação tridimensional que tendem a minimizar ou solucionar estes problemas, como o planejamento virtual da posição dos DATs, o design do aparelho a partir das variações anatômicas, incluindo o posicionamento tridimensional do torno a partir da posição natural da cabeça do indivíduo, bem como a técnica de corticoperfuração guiada, indicada para casos de espessura óssea aumentada, idade avançada, sutura em estágio de maturação avançado e presença de tórus palatino entre outros.

Estes protocolos de planejamento tridimensionais são inéditos. Até o momento observamos apenas protocolos isolados, como por exemplo a análise de maturação da sutura palatina mediana, que após avaliada não possui um protocolo para se potencializar as chances de sucesso, apenas é apresentada como um obstáculo ao clínico.

Sendo assim, este estudo também propõe a apresentação de uma solução completa dos diversos fatores impactantes para o sucesso da técnica MARPE, por isso a necessidade de se realizar um levantamento tão amplo a partir dos exames tomográficos de centenas de pacientes.

3 MATERIAL E MÉTODOS

3.1 Desenho de estudo

Este estudo observacional transversal analisou as variações anatômicas e diferentes possibilidades de planejamento, tratamentos, e novas ferramentas, por meio da análise de tomografias computadorizadas de feixe cônico (TCFC) em pacientes com idade entre 9 e 53 anos de ambos os sexos.

3.2 Aprovação ética

Este estudo foi aprovado pelo Comitê de Ética da Universidade de Mogi da Cruzes (CAAE: 55356821.1.0000.5497 / Número de aprovação: 5.360.812). Não foi necessário o termo de consentimento livre e esclarecido pois todas as imagens de tomografia computadorizada de feixe cônico (TCFC) foram obtidas de um arquivo, e foram solicitadas por ortodontistas, para o planejamento de expansão rápida da maxila associada à DATs (Hyrax híbrido e MARPE). Todos os dados foram anonimizados antes da investigação.

3.3 Critérios de inclusão e exclusão

Os critérios de inclusão foram exames de tomografia do banco de dados do setor de planejamento digital da indústria de ortopedia facial customizada Kika Digital Orthodontics, entre 2019 e 2022, de indivíduos entre 9 e 53 anos, de ambos os sexos, que possuíam deficiência transversal da maxila e necessidade de expansão da maxila com o uso de DATs. Os critérios de exclusão foram indivíduos com fissura nasopalatina, síndromes ou malformações craniofaciais, ou pacientes com indicação para expansão maxilar convencional.

3.4 Mensurações

Para a avaliação das características anatômicas foram utilizadas TCFC apenas da região da maxila. A padronização da posição da cabeça utilizada para a interpretação das imagens da tomografia no software Blue Sky (Blueskybio.com, Blue Sky Bio®) foi realizada de tal forma que o plano palatal fosse posicionado paralelo ao

solo no corte sagital; no corte axial utilizou-se como referência uma linha perpendicular ao solo que passasse simultaneamente sobre a espinha nasal anterior e posterior; e no corte coronal utilizou-se o plano do assoalho da cavidade nasal na região de primeiros molares paralelo ao solo (Pasqua *et al*., 2021).

Todos os casos exigiram a sobreposição da tomografia com os arquivos de escaneamento intrabucal de cada paciente. Isso foi realizado para aumentar a acurácia da avaliação e garantir resultados mais precisos. O protocolo completo desta técnica será descrita a seguir nos artigos.

3.5 Análise estatística

A análise estatística foi individualizada para cada artigo, respectivamente, assim como as citações e referências. Dessa forma, em cada artigo será apresentada sua respectiva análise estatística, bem como as citações, e as referências, seguindo as normas de acordo com a revista na qual o artigo fora publicado.

4 DESENVOLVIMENTO

4.1 Objetivos gerais do trabalho

O objetivo do presente trabalho foi realizar um amplo levantamento das variações anatômicas que podem causar um insucesso da técnica MARPE e apresentar possíveis soluções por meio do planejamento digital, abrangendo a análise de tomografias de pacientes desde uma idade mais jovem até os pacientes mais maduros.

Como soluções apresentamos processos tridimensionais como planejamento virtual da posição dos DATs, o posicionamento do torno expansor, o design do aparelho considerando todas estas variações anatômicas. Como suplemento a estes processos, apresentamos um estudo sobre uma ferramenta adicional, que se trata da perfuração guiada das suturas.

Sendo assim, este estudo se trata de um levantamento inédito, uma vez que até o momento existem apenas protocolos isolados e sem resoluções definitivas. No mais, o estudo propõe uma solução completa para todos os fatores impactantes no sucesso e/ou insucesso da técnica MARPE, destacando a importância de se realizar um levantamento amplo a partir de um banco de dados de exames tomográficos de centenas de pacientes.

Desta forma, apresentaremos os artigos a seguir de acordo com o fluxograma (Figura 1). O primeiro artigo trata das variações anatômicas, o artigo 2 possíveis soluções de instalação virtual frente a estas variações anatômicas, o artigo 3 considera diferentes *designs* frente a variações anatômicas; por meio da cirurgia virtual, e o artigo 4 complementa todas as técnicas citadas anteriormente, pois o mesmo apresenta uma uma ferramenta adicional que se trata das córticoperfurações.

Figura 1 - Fluxograma da estrutura do trabalho

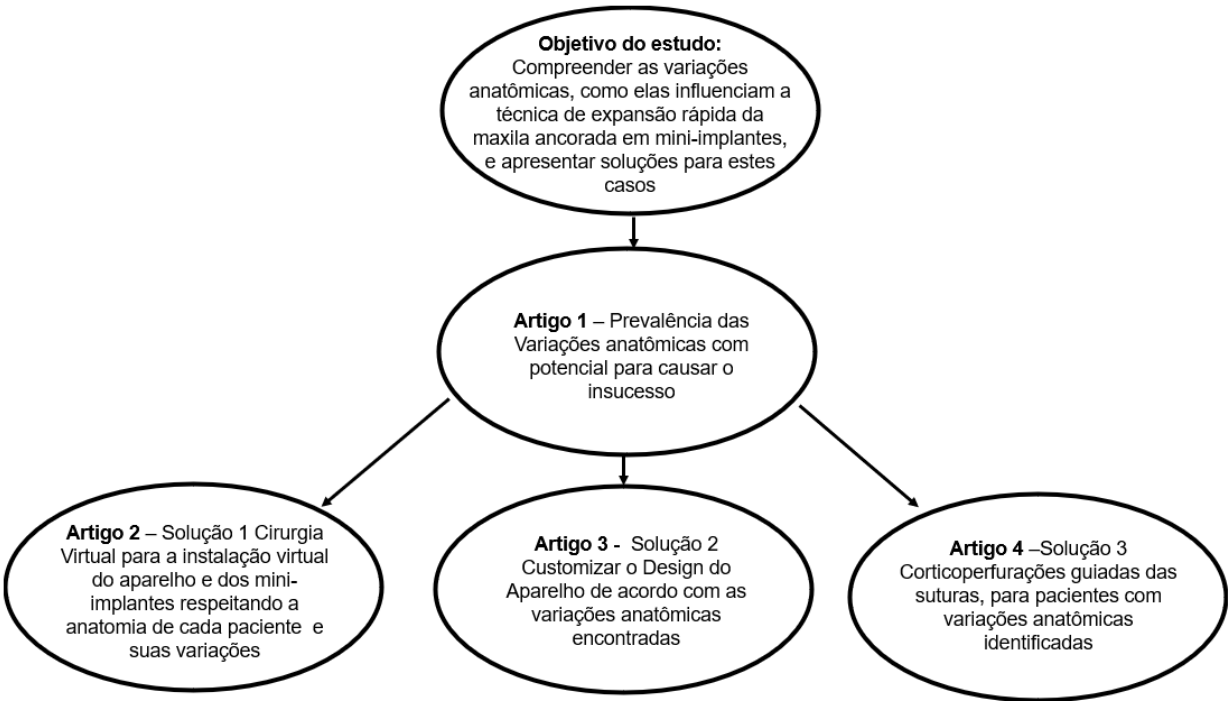

Fonte: Próprio autor

4.2 Status das publicações

Dois dos artigos que apresentamos no presente trabalho já foram publicados, e temos 2 outros artigos que estão em revisão. Abaixo, segue a descrição dos status de cada artigo, seguindo a mesma ordem do fluxograma.

Artigo 1: “Parameters for mini-implant supported rapid maxillary expansion: prevalence of nasomaxillary anatomical variations”. Artigo em revisão na revista “Journal of Orofacial Orthopedics / Fortschritte der Kieferorthopädie”.

Artigo 2: “Surgical Digitally Guided Planning for the Mini-Screw Assisted Rapid Palatal Expansion (MARPE) and Suture Perforation: MARPE Guide”. Publicado como capítulo de livro na revista Intech Open – Current Trends in Orthodontics”. Referência: Barros André C. de Paula Machado Pasqua B, Rino Neto J, Dupart FN. 2022. Surgical Digitally Guided Planning for the Mini-Screw Assisted Rapid Palatal Expansion (MARPE) and Suture Perforation: MARPE Guide [Internet]. Current Trends in

Orthodontics. IntechOpen [Accessed]. Available at: http://dx.doi.org/10.5772/intechopen.

Artigo 3: ”Miniscrew-assisted rapid palatal expansion (MARPE): factors influencing planning”, publicado na revista “Dental Press of Orthodontics”. Referência: André CB, Pasqua BPM, Jacquier GA, Nascimento FD. Miniscrew-assisted rapid palatal expansion (MARPE): Factors influencing planning. Dental Press J Orthod. 2024;29(3):e242439.

Artigo 4: “Guided corticopuncture associated with microimplant-assisted rapid palatal expansion (MARPE): planning variables”, está em revisão na revista “Dental Press of Orthodontics”.

Todos os artigos foram revisados para língua inglesa pela empresa Editage.

4.3 Artigos

4.3.1 Parameters for mini-implant supported rapid maxillary expansion: prevalence of nasomaxillary anatomical variations

Abstract

Purpose: This cross-sectional study aimed to assess the anatomical variations in the nasomaxillary region among patients with transversal maxillary deficiency aged 9 to 53 years, of both sexes, utilizing a database of Cone beam compute tomography (CBCT) scans.

Methods: Two hundred scans were assessed using the Blue Sky software (Blueskybio.com, Blue Sky Bio®). The variables evaluated were: midpalatal and zygomaticomaxillary sutures maturation; midpalatal suture configuration and length; nasal septum deviation; nasopalatine foramen dimension; transverse palatine suture location by dental reference; presence of palatine torus and its length; analysis of maxillary symmetry; occlusal, palatine, and nasal floor plane inclinations; bone defects; and shape of the palate (first premolars and first permanent molars region).

Results: The most common classification for the midpalatal suture was “D” (34%). The extension of the suture (axial section) was, on average, 3.9 mm ± 0.7 greater in men ($p = 0.000$). The pterygopalatine suture was already fused in 88% of

the cases. A high prevalence (46% in total) of patients exhibited an increased size of the nasopalatine foramen. The palatine torus was present in 23% of the total cases. The mean value of the anteroposterior extension of the maxillary torus was 23.6 mm ± 8.5 in women and 25 mm ± 10.6 in men.

Conclusion: We presented anatomical variations that have the potential to cause failure in maxillary expansion therapy, with a higher prevalence observed in men and young patients. These data can guide three-dimensional planning for RME with mini-implants for young and adult patients.

Keywords: Maxillary Expansion; Orthodontic Anchorage Technique; Cone-beam computed Tomography, Anatomic Variation.

Introduction

Rapid maxillary expansion (RME) is the preferred treatment for patients exhibiting transverse maxillary deficiency and posterior crossbite. It is crucial to administer this treatment as early as possible to prevent potential deviations in facial growth.[1] Adult patients are required to undergo a more invasive procedure known as surgically assisted rapid maxillary expansion (SARPE). This high-cost procedure, performed in a hospital setting, involves a delicate postoperative period.

Mini-implants associated with RME offer a less invasive treatment option. The Hybrid Hyrax, a device designed to provide tooth-bone support for growing patients, utilizes bands on the first permanent molars and two orthodontic mini-implants.[2] For adult patients, Mini-screw Assisted Rapid Palatal Expansion (MARPE) is a technique that relies on maxillary expansion supported by four or six mini-implants.[3,4]

Patients widely accept these procedures owing to their less invasive nature and lower cost compared to SARPE.[3,5-8] This technique has demonstrated promising results, including high success rates in adult patients,[5, 9-11] stability of RME results,[12] orthopedic maxillary expansion with minimal side effects,[13,14] and more pronounced orthopedic effects compared to surgery.[15,16]

However, there is a scarcity of studies on anatomical variations that may directly influence the success or failure of the technique.[17,18] Certain anatomical variations determine the design of the appliance, the installation site of the mini-implants, and even the height of the expander. Failure to identify these variations beforehand can lead to the risk of inserting mini-implants in areas with critical structures such as the nasal septum, nasopalatine foramen, or over the maxillary sutures.[19]

Therefore, the aim of this study was to thoroughly identify potential anatomical variations utilizing a database of cone beam computed tomography (CBCT) scans among patients with transversal maxillary deficiency, aged 9–53 years, across both sexes, in the nasomaxillary region. As a second aim, sex-related differences were evaluated.

Methods

This cross-sectional study utilized CBCT scans to examine the anatomical variations in the maxilla of 200 patients aged 9–53 years. Given that there were no previous similar studies in the literature, an adequate sample size calculation could not be performed.

Ethical approval

This study was approved by the Ethics Committee of the University of Mogi da Cruzes (CAAE: 55356821.1.0000.5497; Approval number: 5.360.812).

Inclusion and exclusion criteria

The inclusion criteria encompassed CBCT scans of patients with transverse maxillary deficiency, performed between 2019 and 2023, involving patients aged 9–53 years, irrespective of their sex. The exclusion criteria, however, ruled out CBCT scans from patients with nasopalatine cleft, craniofacial syndromes, or malformations.

Measurements

CBCT was previously obtained using iCAT (Imaging Sciences International, Hatfield, Pennsylvania) with the following settings: 120 kVp, 18 mA; exposure time, 8.9 s; voxel size, 0.2 mm; and a field of view (FOV) of 160 × 60 mm.

Before the assessment, the scans were deidentified with a coded ID number in BlueSky software (Blueskybio.com, Blue Sky Bio®) to avoid bias. Anatomical features of the maxillary region were assessed using CBCT scans, using BlueSky software (Blueskybio.com, Blue Sky Bio®), a reference software for guided protocols in Orthodontics.[17,20] The orientation of the head position was determined based on a previous methodology.[7] The variables evaluated from the scans are detailed in Table 1. To enhance the accuracy of the evaluation, some measurements necessitated a superimposition of the CBCT scan and the intraoral scan files (obtained from Trios Pod Version, 3Shape, Copenhagen, Denmark) for each patient (Figures 1 and 2). By superimposing these files, it was possible to better identify the boundary between the tongue and palate, for instance, as these structures may be overlapped on the CT scan. Midpalatal an zygomaticomaxillary sutures maturation were assessed by the method developed by Angelieri.[21,22]

Table 1 - Description of the parameters evaluated in the tomography.

Parameter	Description
Midpalatal suture maturation stage (MPSM)	Assessment of midpalatal suture maturation (CBCT assessment) according to Angelieri *et al* 2013.
Zygomaticomaxillary suture maturation stage (ZMSM)	Assessment of zygomaticomaxillary suture maturation (CBCT assessment) according to Angelieri *et al* 2013.
Pterygopalatine suture anatomy (Pteryg.)	Axial section assessment to analyze the fusion between the lateral and medial lamina of the pterygoid process
Configuration of the midpalatal suture - axial plane (MPS-AXIAL)	Axial section assessment of the configuration of the midpalatal suture, which can be straight or sinuous.
Configuration of the midpalatal suture – coronal plane (MPS-CORONAL)	Coronal section assessment of the configuration of the midpalatal suture, which can be, straight, sinuous, or inclined.
Midpalatal suture length (MPS- LENGHT)	Measurement of the midpalatal suture in the axial section between the anterior and posterior nasal spine points (value in millimeters).
Coincidence between palatine raphe and midpalatal suture (RAPHE-MPS)	Evaluation of the coincidence between palatine raphe and midpalatal suture (evaluation performed by superimposing the tomography and intraoral scanning) (Figure 1).
Coincidence between nasal septum and midpalatal suture (SEPTUM-MPS)	Evaluation of the relationship between suture and septum in the coronal section, which may or may not coincide.

Nasal septum deviation (SEPTUM)	Nasal septum deviation assessment.
Nasopalatine foramen dimension (FO)	Distance from the lateral limits of the nasopalatine foramen, measured in the axial section of the tomography.
Transverse palatine suture Location by dental reference (TRANS-TEETH)	Location, by dental reference, of transverse palatine suture, through the axial cut (1st molar center, 2nd molar center, 1st molar distal, 2nd molar distal)
Coincidence of the position of the transverse palatine suture with the soft tissue limit (TRANS-SOFT)	Evaluation of the coincidence of the location of the transverse palatine suture with the soft/hard palate limit (superimposing of the tomography and intraoral scanning)(Figure 2).
Presence of palatine torus (TORUS)	Presence of palatine torus (sagittal section).
Palatine tórus length (TORUS-LENGHT)	Measurement of the lateral limits of the palatine torus (sagittal section).
Vertical asymmetry of the maxilla in the coronal section (ASSYM-CORONAL)	Evaluation of the bone symmetry between the right and left sides of the maxilla in the coronal section.
Inclination of the upper right central incisor (INC-11)	Measurement of the inclination between the long axis of the upper central incisor on the right side with respect to the palatal plane – measurement taken in the sagittal section.
Occlusal plane inclination (OPL-INC)	Assessment of the inclination of occlusal plane (straight or inclined – coronal section).
Palatine plane inclination (PALAT.PL. INC)	Assessment of the inclination of the palatal plane (straight or inclined – coronal section).
Nasal floor plane inclination (NASAL.PL.INC)	Assessment of the inclination of the palatal plane (straight or inclined – coronal section).
Bone defects along the maxilla in the sagittal cut along the suture (SAGGITAL-DEFECTS)	Presence of bone defects in the maxilla along the sagittal section.
Absence of bone on the floor of the nasal cavity (CORONAL-DEFECTS)	Presence of bone defects in the maxilla along the coronal section.
Shape of the palate in the region of the first premolars (PALATE 1PM)	Assessment of the shape of the palate in the region of the first premolars (W,U,V or plane – Figure 3)
Shape of the palate in the region of the first permanent molars (Palate 1M)	Assessment of the shape of the palate in the region of the first permanent molars (W,U,V or plane – Figure 3)

Fonte: Próprio autor

Figure 1 - Assessment of the relation of the mid-palatal suture with the palatine raphe.

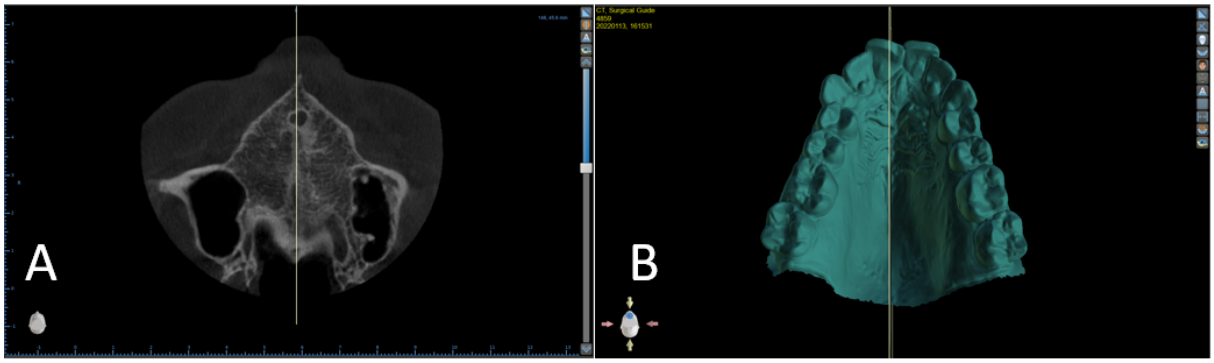

Fonte: Próprio autor

Figure 2 - Assessment of the relation of the transverse palatine suture with the soft/hard tissue boundary.

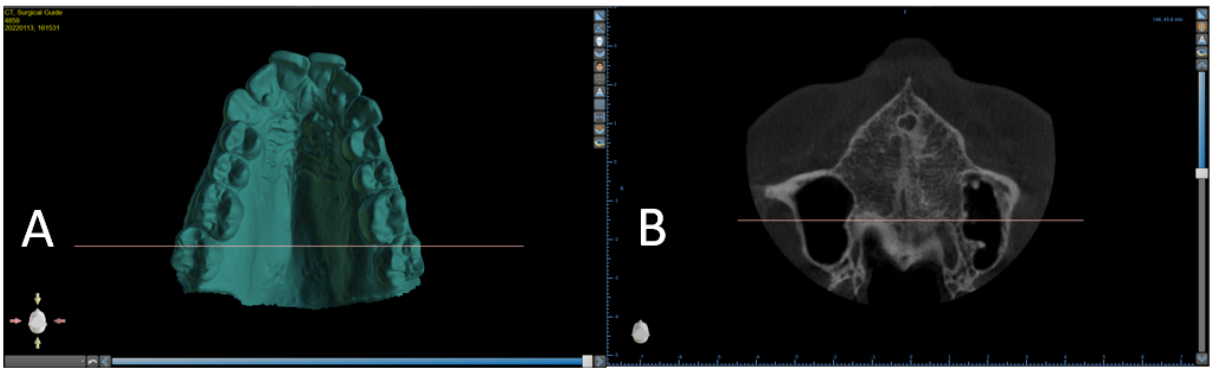

Fonte: Próprio autor

Figure 3 - Different shapes of the palate.

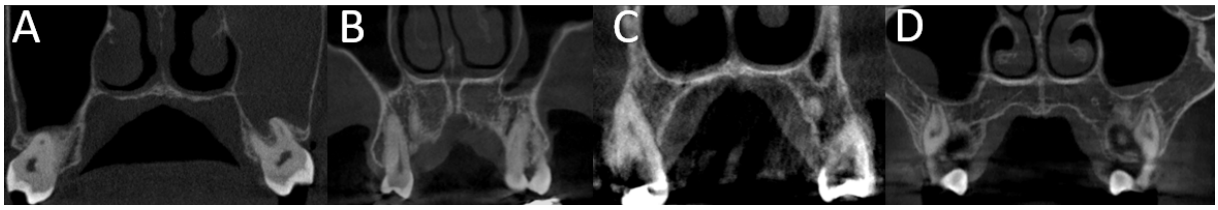

Fonte: Próprio autor

Statistical analysis

Regarding the reproducibility and repeatability of the measurements obtained from the CBCT scans, the measurements were repeated on 20% of the total sample 4 weeks after the first measurement. The method error was calculated using the concordance correlation coefficient.[23] The significance level was set at 5%.

Numerical variables were analyzed using means ± SD or medians and interquartile range. Patient sex distribution was evaluated using absolute and relative frequencies, with differences in sex distribution confirmed through chi-square tests or Fisher's exact tests.[23] Anatomical variables were also assessed using absolute and relative frequencies, with sex distribution differences verified using Mann–Whitney tests. Pearson's correlations were used to determine potential relationships between the age variable and tomographic variables.[23] All analyses were conducted using IBM-SPSS for Windows version 20.0 software. Tests were performed at a 5% significance level.

Results

Method error

The average correlation coefficient obtained for the numeric variables evaluated in this study was 0.917 ± 0.11.

Distribution of sex and sex and anatomical data: Baseline data, prevalence and comparison between sexes

The sample presented a median age and interquartile range of 25.9 (15.3–34.8) and included 100 female patients with a median age of 26.2 (24–28.5) and 100 male patients with a median age of 25.6 (23.2–27.9)(Table 2).

No statistically significant difference was observed between women and men in terms of the distribution of skeletal maturation stages of the midpalatal suture and zygomaticomaxillary suture (MPSM and ZMSM)(Table 2). When considering the total number of patients evaluated, classification “D” (34%) was the most common for the median palatine suture, while classification "A" was the least frequent (7.5%).

In relation to the pterygopalatine suture (Pteryg.), it was noted that fusion had already occurred in 88% of cases across both sexes (Table 2). As for the median palatine suture (MPS-AXIAL), the majority of patients exhibited a sinuous aspect in the axial section (64.5%) and an inclined aspect in the coronal section (MPS-CORONAL) (59%). No statistically significant differences were detected in either evaluation with respect to sex (Table 2).

Both sexes exhibited an 85% prevalence of the midpalatal suture coinciding with the palatine raphe (RAPHE-MPS). Additionally, an 81% overall prevalence was observed for the nasal septum aligning with the midpalatal suture (SEPTUM-MPS).

Table 2 - Characterization of the sample and comparison of anatomical characteristics between sexes (Mann-Whitney or Fisher's exact test)

PARAMETER	BOTH SEXES PREVALENCE	FEMALE PREVALENCE	MALE PREVALENCE	P
GENDER (%)	200(100%)	100 (50%)	100 (50%)	1.000
AGE (YEARS) MÉDIA ± DP	26.9 ± 11.5	26.2 (24 – 28.5)	25.6 (23.2 – 27.9)	0.431
MPSM (%)				0.099
A	15 (7.5%)	8 (8%)	7 (7%)	
B	41 (20.5%)	17 (17%)	24 (24%)	
C	28 (14%)	13 (13%)	15 (15%)	
D	68 (34%)	33 (33%)	35 (35%)	
E	46 (23%)	29 (29%)	17 (17%)	
NOT ASSESSD	2 (1%)	0	2 (2%)	
ZMSM (%)				0.080
A	5 (2.5%)	1 (1%)	4 (4%)	
B	20 (10%)	12 (12%)	8 (8%)	
C	14 (7%)	7 (7%)	7 (7%)	
D	12 (6%)	6 (6%)	6 (6%)	
E	21 (10.5%)	16 (16%)	5 (5%)	
NOT ASSESSED	128 (64%)	58 (58%)	70 (70%)	
PTERYG. (%)				0.423
MERGED	176 (88%)	89 (89%)	87 (87%)	
NOT MERGED	14 (7%)	8 (8%)	6 (6%)	
NOT ASSESSED	10 (5%)	3 (3%)	7 (7%)	
MPS–AXIAL (%)				0.423
STRAIGHT	69 (34.5%)	36 (36%)	33 (33%)	
SINUOUS	129 (64.5%)	64 (64%)	65 (65%)	
NOT ASSESSED	2 (1%)	0	2 (2%)	
MPS-CORONAL (%)				0.443
STRAIGHT	82 (41%)	42 (42%)	40 (40%)	
SINUOUS	118 (59%)	58 (58%)	60 (60%)	
RAPHE–MPS (%)				0.578
COINCIDENT	170 (85%)	85 (85%)	85 (85%)	
NOT COINCIDENT	38 (15%)	15 (15%)	15 (%)	
SEPTUM-MPS (%)				0.103
COINCIDENT	162 (81%)	85 (85%)	77 (77%)	
NOT COINCIDENT	38 (18.9%)	15 (15%)	23 (23%)	

SEPTUM (%)				0.171
RIGHT SIDE	74 (37%)	35 (35%)	39 (39%)	
LEFT SIDE	94 (47%)	44 (44%)	50 (50%)	
NO DEVIATION	32 (15.9%)	21 (21%)	11 (11%)	
FO (%)				0.450
NO INCREASE	108 (54%)	58 (58%)	50 (50%)	
DIMENSION BETWEEN 0.4 AND 0.6MM	67 (33,5%)	32 (32%)	35 (35%)	
DIMENSION > 0.6MM (CYST)	25 (12,5%)	10 (10%)	15 (15%)	
TRANS-TEETH (%)				0.123
1ST MOLAR CENTER	2 (1%)	1 (1%)	1 (1%)	
2ND MOLAR CENTER	77 (35%)	45 (45%)	32 (32%)	
1ST MOLAR DISTAL	70 (35%)	35 (35%)	35 (35%)	
2ND MOLAR DISTAL	50 (25%)	19 (19%)	31 (31%)	
TRANS-SOFT (%)				0.126
COINCIDENT	100 (50%)	46 (46%)	54 (54%)	
NOT COINCIDENT	96 (48%)	53 (53%)	43 (43%)	
NOT ASSESSED	4 (2%)	1 (1%)	3 (3%)	
TORUS (%)				0.121
PRESENT	46 (23%)	26 (26%)	20 (20%	
ABSENT	154 (77%)	74 (74%)	80 (80%)	
ASSYM-CORONAL (%)				0.500
RIGHT SIDE	119 (59.5%)	59 (59%)	60 (60%)	
LEFT SIDE	79 (39.5%)	40 (40%)	39 (39%)	
NOT ASSESSED	2 (1%)	1 (1%)	1 (1%)	
OPL.INC (%)				0.110
INCLINED	124 (62%)	57 (57%)	67 (67%)	
NOT INCLINED	75 (37.5%)	42(42%)	33 (33%)	
NÃO AVALIADOS	(0,5%)	1 (1%)	0	
PALAT.PL.INC (%)				0.043*
INCLINED	115 (57.5%)	51 (51%)	64 (64%)	
NOT INCLINED	85 (42.5%)	49 (49%)	36 (36%)	
NASAL.PL.INC (%)				0.024*
INCLINED	95 (47.5%)	40 (40%)	55 (55%)	
NOT INCLINED	105 (52.5%)	60 (60%)	45 (45%)	
SAGITTAL-DEFECTS (%)				0.102
PRESENT	55 (27.5%)	23 (23%)	32 (32%)	

ABSENT	145 (72.5%)	77 (77%)	68 (68%)	
CORONAL DEFECTS (%)				0.088
PRESENT	66 (33%)	28 (28%)	38 (38%)	
ABSENT	134 (67%)	72 (72%)	62 (62%)	
PALATE 1PM (%)				0.245
PLANE	1 (0.5%)	1 (1%)	0	
V	5 (2.5%)	4 (4%)	1 (1%)	
U	97 (48.5%)	55 (55%)	42 (42%)	
W	90 (45%)	39 (39%)	51 (51%)	
PALATE 1M (%)				0.903
PLANE	53 (26.5%)	27 (27%)	26 (26%)	
V	1 (0.5%)	0	1 (1%)	
U	87 (43.5%)	45 (45%)	42 (42%)	
W	59 (29.5%)	28 (28$%)	31 (31%)	

□ ***SPEARMAN CORRELATION***

P<.05; **P<.01; ***P<.001; ****P<.0001

Fonte: Próprio autor

On average, the midpalatal suture length was 3.9 mm ± 0.7 longer in male patients, with a statistically significant difference (p = 0.000) (Table 3).

Table 3 - Numerical data of the variables evaluated and comparison between genders (Student's t-test).

Anatomical measurement	**BOTH SEXES**		**FEMALE**		**MALE**		**Mean difference ± SE**	**Confidence interval**		**P value**
	N	Mean ± SD	N	Mean ± SD	N	Mean ± SD		**Lower**	**Upper**	
MPS-LENGHT (mm)	194	49.6 ± 5.4	98	47.7 ± 5.8	96	51.6± 4.1	-3.9 ± 0.7	-5.3	-2.4	0.000****
TORUS-LENGHT (mm)	45	24.3 ± 9.3	26	23.6 ± 8.5	19	25 ± 10.6	-1.4 ± 2.8	-7;2	4.3	0.618

INC 11 (°)	194	111.9 ± 8.1	97	111.9 ± 8.6	97	111.7 ± 7.6	0.2 ± 1.1	-2.1	2.5	0.834
SD: standard deviation										
SE: standard error										
N: sample size										
**P<.05; **P<.01; ***P<.001; ****P<.0001*										

Fonte: Próprio autor

Overall, a low incidence of cases without nasal septal deviation (SEPTUM) was observed (15.9%). The deviation was predominantly found on the left side (Table 2), with no significant disparity between sexes.

The prevalence of patients exhibiting an enlarged nasopalatine foramen was notably high (FO), accounting for 46% of all cases. The occurrence of a nasopalatine foramen cyst, characterized by a size exceeding 6 mm, was observed in 10% of women and 15% of men (this disparity did not yield a statistically significant difference).

The transverse palatine suture was predominantly located in the central region of the 2nd molar (45%) in women (Table 2). In men, the suture was most found in the distal region of the 1st molar (35%). Concerning the suture's relationship with the boundary between the hard and soft palate, it coincided in 50% of the cases, with no statistically significant sex differences.

The palatine torus was present in 23% of all cases, exhibiting a marginally higher prevalence in women, though the difference was not statistically significant. The average anteroposterior extension of the maxillary torus measured 23.6 mm ± 8.5 in women and 25 mm ± 10.6 in men (Table 3). No statistically significant difference was observed between the sexes.

The prevalence of vertical bone asymmetry in the coronal section (ASSYM-CORONAL) was equivalent between sexes, with the right side being thicker in 59.5% of all cases (Table 1). The occlusal plane (POL-INC) exhibited a higher inclination in men (67%) than in women (57%). Both the inclination of the palatal plane (PALAT.PL.INC.) and the nasal floor plane (NASAL.PL.INC.) were more prevalent in men, accounting for 64% and 55% of cases, respectively. These differences were statistically significant (p= 0.043; p= 0.024).

Regarding the presence of bone defects, a prevalence of 23% in women and 38% in men was observed in the maxilla's sagittal section (SAGGITAL-DEFECTS). However, the difference was not statistically significant. This trend persisted in the coronal section of the nasal cavity (CORONAL-DEFECTS), with defects present in 28% of women and 38% of men.

In the premolar region, the palate shape exhibited a higher prevalence of the U-shape (55%) in women, followed by the W-shape (39%). Only 4% of female patients had a flat shape, and a single case of a V-shape (1%) was observed. In contrast, the most common palate shape in male patients was W-shaped (51%), followed by U-shaped (42%).

In the molar region, the U-shape was the most prevalent among women, accounting for 45% of the cases. This was followed by the W-shape at 28%, while 27% of the patients exhibited a flat shape. Notably, no female patient presented a V-shape in the molar region. In contrast, among men, the U-shape was also the most common, with a prevalence of 42%. This was followed by the W-shape at 31%, and 26% of the patients had a flat shape. Only one male patient exhibited a flat shape (Table 2).

Correlations of anatomical data with age (Table 4)

A positive correlation was observed between age and the skeletal maturation of both the median palatine suture (0.442) and the zygomaticomaxillary suture (0.604). Conversely, a negative correlation was found between age and the fusion of the pterygomaxillary suture ($r = -0.182$).

A positive correlation was found between patient age and nasopalatine foramen size ($r = 0.160$). Conversely, a negative correlation was found between age and vertical asymmetry ($r = -0.247$).

Negative correlations were observed between age and bone defects in both the maxilla (-0.322) and the floor of the nasal cavity (-0.257).

A negative correlation was observed between age and the shape of the palate. As the age of the patient increased, the likelihood of a U-shaped palate, as opposed to a W-shaped one, also increased.

Table 4. Correlation of assessed parameters with age. Spearman's correlation.

Parameters	MPSM	ZMSM	PTERYG	MPS-AXIAL	SEPTUM-MPS	SEPTUM	FO	ASSYM-CORONAL	OPL.INC	SAGITTAL-DEFECTS	CORONAL-DEFFECTS	PALATE 1PM	PALATE 1M
Age	r 0.442 p 0.000*** n 198	r 0.604 p 0.000*** n 72	r -0.182 p 0.012* n 190	r 0.005 p 0.947 n 198	r 0.044 p 0.539 n 0.200	r -0.014 p 0.846 n 200	r 0.160 p 0.023* n 200	r – 0.247 p 0.000*** n 198	r -0.094 p 0.184 n 199	r -0.332 p 0.000*** n 200	r -0.257 p 0.000*** n 200	r -0.048 p0.500 n 200	r -0.195 p 0.006** n 200
N: sample size **P<.05; **P<.01; ***P<.001; ****P<.0001*													

Discussion

The objective of this paper was to discuss the potential factors that influence the success and failure of MARPE and Hybrid Hyrax. We observed a high prevalence of patients with midpalatal suture in advanced stage (Table 3).[24,25] The pterygomaxillary suture in most patients was found to be interdigitated, suggesting that this fusion occurs earlier than in other sutures. However, recent studies have demonstrated no correlation between suture maturation evaluation and the success of MARPE.[26,27]

The extension of the midpalatal suture is understood to be a significant factor in expansion techniques, with greater extension correlating to increased resistance to opening. In this study, male patients exhibited a greater extension of this parameter by approximately 4 mm (p= 0.000) (Table 3). This factor may explain the higher incidence of MARPE treatment failure in men.[18]

The location, inclination, and shape of sutures play a crucial role as they can affect the placement of mini-implants or corticopuncture.[17,28] Additionally, they can influence the design of the appliance and the number of mini-implants required.[17,29] Almaqrami *et al*.(2020),[30] discovered that an asymmetric initial configuration of the midpalatal suture is a risk factor for asymmetric expansion. This finding is particularly significant given that 64.5% of patients exhibited a sinuous aspect of this suture. This

emphasizes the necessity for a tailored approach for each patient, incorporating guided planning.[17,19]

The transverse palatine suture, if overlaid with mini-implants, has a high potential for failure. In the present study, this suture often displayed different directions between the left and right sides of the maxilla. Furthermore, in men, this suture is more commonly found in the distal region of the first molar (35%) (Table 2). This poses a risk of failure as the literature recommends positioning mini-implants based on teeth.[31,32]

A high prevalence of nasal septal deviation cases was observed, accounting for 84.9% (Table 1). Installing a mini-implant over it significantly increases the risk of treatment failure. Therefore, it is evident that the virtual guided installation of mini-implants should consistently be recommended for MARPE.[17]

The prevalence of a palatal torus, found in 23% of all cases, along with its location and volume. The average measurement of the anteroposterior extension of the maxillary torus was 23.6 mm ± 8.5 in women and 25 mm ± 10.6 in men (Table 2). Upon diagnosis of a torus, supplementary measures for the MARPE technique, such as corticopuncture (suture weakening), or the addition of mini-implants to enhance anchorage, should be premeditated.[4,17]

There was a high prevalence (46% in total) of patients with an enlarged nasopalatine foramen, with the majority of cases presenting a size between 4 and 6 mm. In such instances, strategic planning enables the adjustment of the mini-implants' angulation to prevent interference with the nasopalatine canal.

The nasopalatine foramen cyst prevalence was notably high, ranging from 10 to 15%. Utilizing industrialized MARPE appliances without digital planning in these instances is ill-advised owing to the fixed lateral distance (6 mm) between the mini-implants, which necessitates their insertion within the nasopalatine canal. A positive correlation was observed between age and the size of the nasopalatine foramen (Table 4), indicating that as the nasomaxillary complex develops, the size of the foramen also increases.

The right side of the maxilla was found to be thicker in 59.5% of cases (asymmetry), suggesting the use of variously sized mini-implants. In digital planning, the dimensions of the mini-implants are determined based on accurate measurements and guides, which can reproduce this positioning in a clinical setting.

Understanding the shape of the palate is crucial for the biomechanics of dental appliances. For instance, when an appliance is fitted to a U-shaped or straight palate surface, it conforms to the palate. This conformity enhances the overall moment of force by evenly distributing the exerted stress. Conversely, appliances fitted on M or V-shaped surfaces often inadequately adapt, leaving a substantial gap between the appliance and the bone tissue on one side. This reduces the bone's contribution and decreases the likelihood of successful treatment.

The occlusal plane exhibited a steeper inclination in men (67%), a factor that also correlates positively with growth (as indicated by the correlation between age and occlusal plane inclination in Table 4). This suggests that as a patient matures, all bone thicknesses increase, accounting for the higher prevalence of bone gaps in children compared to adults. Early detection of bone gaps along the nasal floor is crucial to avoid using this region as a site for mini-implant installation. Subsequent planning for the insertion site of mini-implants should not rely on references in teeth29 or soft tissues.[2]

The incidence of a tilted palatal plane and a tilted nasal floor plane was higher in men, accounting for 64% and 55% of cases, respectively. This information is crucial as the nasal cavity floor must be taken into account when designing a mini-implant supported maxillary expansion appliance. A tilted nasal floor can necessitate alterations to the appliance design and the size of the mini-implants. To prevent facial asymmetry in the patient, appliances should be designed with the expander screw as horizontal as possible.

We noted that as patients mature, they may experience bone resorption, which could explain the prevalence of thin bones in adults. Conversely, younger patients often retain an irregular M-shaped bone structure (Table 4). Therefore, planning for the Hybrid Hyrax (growing phase) remains crucial. Despite these observations, further longitudinal studies are required to determine whether patients experience bone loss

or bone apposition, such as the filling of bone gaps. While the planning for MARPE and Hybrid Hyrax is entirely individualized for each patient, understanding the prevalence of palate shape is vital. The customization of mini-implant angulation and the variation in implant size may be more common than previously thought, as suggested by the results of this study.

Limitations and Generalizability

The primary limitations of this study stem from its cross-sectional design. The use of retrospective data collection could potentially introduce bias. To mitigate selection bias, all tomographies meeting the inclusion criteria were incorporated into the study.

Conclusions

Anatomical variations were found to be more prevalent in men, and certain variations were more pronounced in younger patients.

Understanding these alterations can aid in strategizing by allocating additional resources, thereby enhancing the likelihood of success and improving the quality of maxillary expansion therapies.

The evidence suggests a necessity for three-dimensional guided planning, particularly for younger male patients.

References

1. Proffit WR, Fields HW, Sarver DM. Contemporary Orthodontics. St. Louis: Mosby; 2007. Chapter 6, Grade 4 Severe Need Treatment; p.225 e226. 2007

2. Wilmes B, Nienkemper M, Drescher D. Application and effectiveness of a miniimplant-and tooth-borne rapid palatal expansion device: the hybrid hyrax. World J Orthod. 2010 Jan;11:323–30.

3. Lee KJ, Park YC, Park JY, Hwang WS. Mini-implants-assisted nonsurgical palatal expansion before orthognathic surgery for a patient with severe mandibular prognathism. A Orthod Dentofacial Orthop. 2010; (138):830-839. https://doi.org/10.1016/j.ajodo.2007.10.065

4. Cury SEN, Mondelli AL, André CB, Iared W, Guerra JGP, Rovira J, Berni L. Protocolo diferencial para a técnica MARPE em pacientes com variação no volume ósseo do palato. Rev Clín Ortod Dental Press 2019;18(4):116-129.

5. Choi SH, Shi KK, Cha JY, Park YC, Lee KJ. Nonsurgical miniscrew-assisted rapid maxillary expansion results in acceptable stability in young adults. Angle Orthod. 2016;86(5):713-720. doi:10.2319/101415-689.1

6. GunyuzTM, Germec-Cakan D, Tozlu M. Periodontal, dentoalveolar, and skeletal effects of tooth-borne and tooth-bone-borne expansion appliances. Am J Orthod Dentofacial Orthop. 2015 Jul;148(1):97-109. doi: 10.1016/j.ajodo.2015.02.022

7. Pasqua BPM, André CB, Paiva JB, Tarraf NE, Wilmes B, Rino-Neto J. Dentoskeletal changes due to rapid maxillary expansion in growing patients with tooth-borne and tooth-bone-borne expanders: A randomized clinical trial. Orthod Craniofac Res. 2022 Nov;25(4):476-484. doi: 10.1111/ocr.12559.

8. Inchingolo, Alessio Danilo *et al*. Rapid Maxillary Expansion on the Adolescent Patient: Systematic Review and Case Report. Children (Basel). 2022 Jul 14;9(7):1046. doi: 10.3390/children9071046.

9. Ahn YS, Choi SH, Lee KJ, Jung YS, Baik HS, Yu HS. Stability of bimaxillary surgery involving intraoral vertical ramus osteotomy with or without presurgical miniscrew-assisted rapid palatal expansion in adult patients with skeletal Class III malocclusion. Korean J Orthod. 2020;50(5):304-313. doi:10.4041/kjod.2020.50.5.304

10. Colak O, Paredes NA, Elkenawy I, Torres M, Bui J, Jahangiri S, Moon W. Tomographic assessment of palatal suture opening pattern and pterygopalatine suture disarticulation in the axial plane after midfacial skeletal expansion. Prog Orthod. 2020 Jul 20;21(1):21. doi: 10.1186/s40510-020-00321-9.

11. Kapetanović A, Odrosslij BMMJ, Baan F, *et al*. Efficacy of Miniscrew-Assisted Rapid Palatal Expansion (MARPE) in late adolescents and adults with the Dutch

Maxillary Expansion Device: a prospective clinical cohort study. Clin Oral Investig. 2022;26(10):6253-6263. doi:10.1007/s00784-022-04577-9

12. Lim HM, Park YC, Lee KJ, Kim KH, Choi YJ. Stability of dental, alveolar, and skeletal changes after miniscrew-assisted rapid palatal expansion. Korean J Orthod. 2017 Sep;47(5):313-322. doi: 10.4041/kjod.2017.47.5.313.

13. Celenk-Koca T, Erdinc AE, Hazar S, Harris L, English JD, Akyalcin S. Evaluation of miniscrew-supported rapid maxillary expansion in adolescents: A prospective randomized clinical trial. Angle Orthod. 2018;88(6):702-709. doi:10.2319/011518-42.1

14. Zong, C., Tang, B., Hua, F., He, H., & Ngan, P. Skeletal and dentoalveolar changes in the transverse dimension using microimplant-assisted rapid palatal expansion (MARPE) appliances. Seminars in Orthodontics. 2019;25(1):46-59.

15. Naveda, R., Dos Santos, A. M., Miranda, F., da Cunha Bastos, J. C., & Garib, D. Immediate dentoskeletal and periodontal effects of miniscrew-assisted rapid palatal expansion: Comparison between young vs middle-aged adults. Am J Orthod Dentofacial Orthop. 2023 Apr 9:S0889-5406(23)00164-6. doi: 10.1016/j.ajodo.2023.02.014.

16. de Oliveira CB, Ayub P, Ledra IM, Murata WH, Suzuki SS, Ravelli DB, Santos-Pinto A. Microimplant assisted rapid palatal expansion vs surgically assisted rapid palatal expansion for maxillary transverse discrepancy treatment. Am J Orthod Dentofacial Orthop. 2021 Jun;159(6):733-742. doi: 10.1016/j.ajodo.2020.03.024.

17. André CB, Pasqua BPM, Rino-Neto J, Dupart FN (October 2nd 2021). Surgical Digitally Guided Planning for the Mini-Screw Assisted Rapid Palatal Expansion (MARPE) and Suture Perforation: MARPE Guide [Online First], IntechOpen, DOI: 10.5772/intechopen.100226.

18. Jeon JY, Choi SH, Chung CJ, Lee KJ. The success and effectiveness of miniscrew-assisted rapid palatal expansion are age- and sex-dependent. Clin Oral Investig. 2022 Mar;26(3):2993-3003. doi: 10.1007/s00784-021-04281-0.

19. André CB. MARPE guide: from consolidation to technique evolution. Clin Orthod. 2020 Oct-Nov;19(5):00-0

20. Meda RG, Sans FA, Esquivel J, Zufía J. Impacted maxillary canine with curved apex: Three-dimensional guided protocol for autotransplantation. Journal of Endodontics. 2022;48(3):379-387.

21. Angelieri F, Cevidanes LH, Franchi L, Gonçalves JR, Benavides E, McNamara JA Jr. Midpalatal suture maturation: classification method for individual assessment before rapid maxillary expansion. Am J Orthod Dentofacial Orthop. 2013 Nov;144(5):759-69. doi: 10.1016/j.ajodo.2013.04.022.

22. Angelieri F, Franchi L, Cevidanes LHS, Hino CT, Nguyen T, McNamara JA Jr. Zygomaticomaxillary suture maturation: A predictor of maxillary protraction? Part I - A classification method. Orthod Craniofac Res. 2017 May;20(2):85-94. doi: 10.1111/ocr.12143.

23. Kirkwood BR and Sterne JAC (2006) Essential medical statistics. 2nd ed. Blackwell Science: Massachusetts, USA, 502.

24. Jang H, Kim SC, Chaea JM. Relationship between maturation indices and morphology of the midpalatal suture obtained using cone-beam computed tomography images. Korean J Orthod. 2016;46:345–355. doi: 10.4041/kjod.2016.46.6.345.

25. Luz, C. N., Pasqua, B. D. P. M., Paiva, J. B., & Rino-Neto, J. (2022). Cervical vertebrae maturation assessment as a predictive method for midpalatal suture maturation stages in 11-to 14-year-olds: Retrospective study. Clinical and Investigative Orthodontics, 81(1), 43-49. Doi: 10.1080/13440241.2022.2042036

26. Jesus AS, Oliveira CB, Murata WH, Suzuki SS, Santos-Pinto AD. Would midpalatal suture characteristics help to predict the success rate of miniscrew-assisted rapid palatal expansion? Am J Orthod Dentofacial Orthop. 2021 Sep;160(3):363-373. doi: 10.1016/j.ajodo.2020.04.035. Oliveira, C. B., Ayub, P., Angelieri, F., Murata, W. H., Suzuki, S. S., Ravelli, D. B., & Santos-Pinto, A. (2021). Evaluation of factors related to the success of miniscrew-assisted rapid palatal expansion. The Angle Orthodontist, 91(2), 187-194.

27. Jesus AS, Oliveira CB, Murata WH, Suzuki SS, Santos-Pinto AD. Would midpalatal suture characteristics help to predict the success rate of miniscrew-assisted rapid palatal expansion? Am J Orthod Dentofacial Orthop. 2021 Sep;160(3):363-373. doi: 10.1016/j.ajodo.2020.04.035.

28. Meirelles CM, Ferreira RM, Suzuki H, Oliveira CB, Souza de Jesus A, Garcez AS, Suzuki SS. Analysis of factors associated with the success of microimplant-assisted rapid palatal expansion. Am J Orthod Dentofacial Orthop. 2023 Jul;164(1):67-77. doi: 10.1016/j.ajodo.2022.10.029.

29. Cantarella D, Savio G, Grigolato l, Zanata P, Berveglieri C, Lo Giudice A, Isola G, Del Fabbro M, Moon W. A new methodology for the digital planning of micro-implant-supported maxillary skeletal expansion. Med. Devices Evid. Res. 2020;13:93-106.

30. Almaqrami BS, Alhammadi MS, Al-somairi MAA, ALyafrusee, ES, Xiong H, He H. Three-dimensional assessment of asymmetric mid-palatal suture expansion assisted by a customized microimplant-supported rapid palatal expander in non-growing patients: Uncontrolled Clinical Trial. Orthod Craniofac Res. 2021;25(2): 234-242.

31. Moon, H. W., Kim, M. J., Ahn, H. W., Kim, S. J., Kim, S. H., Chung, K. R., & Nelson, G. (2020). Molar inclination and surrounding alveolar bone change relative to the design of bone-borne maxillary expanders: A CBCT study. The Angle orthodontist, 90(1), 13–22. doi: 10.2319/050619-316.1.

32. Brunetto DP, Sant'Anna EF, Machado AW, Moon W. Non-surgical treatment of transverse deficiency in adults using Microimplant-assisted Rapid Palatal Expansion (MARPE). Dental Press J Orthod. 2017;22(1):110–25. https://doi.org/10.1590/2177-6709.22.1.110-125.sar.

4.3.2 Surgical Digitally Guided Planning for the Mini-Screw Assisted Rapid Palatal Expansion (MARPE) and Suture Perforation: MARPE Guide

Chapter

Surgical Digitally Guided Planning for the Mini-Screw Assisted Rapid Palatal Expansion (MARPE) and Suture Perforation: MARPE Guide

Cristiane Barros André, Bruno de Paula Machado Pasqua, José Rino Neto and Fábio Dupart Nascimento

Abstract

The surgical planning digitally guided for the mini-screw assisted rapid palatal expansion (MARPE) technique consists of a three-dimensional positioning of MARPE and its mini-implants by a nasomaxillary anatomic evaluation. This technique also includes the simulation of the perforation areas on the midpalatal and transpalatal sutures. This type of planning is performed by superimposing the patients' files (STL and DICOM). Correct positioning without colliding with the lateral tissues of the palate and the bicortical positioning of each mini-implant are important components of the case study. The MARPE device permits individualization of the height of the mini-implant rings in each region. To avoid incorrect insertion of the drill, the location of the midpalatal and transpalatal sutures was determined using digital planning. A positioning that avoids contact with important structures, such as the nasopalatine canal, while permitting bicortical drilling of the sutures is recommended. Then, a guide that reproduces MARPE positioning and another guide that reproduces the perforations are fabricated, providing exact reproducibility as performed virtually.

Keywords: orthodontic anchorage procedures, palatal expansion technique, skeletal anchorage, cone-beam computed tomography

1. Introduction

The mini-screw assisted rapid palatal expansion (MARPE) technique comprises rapid maxillary expansion (RME) in adult patients using a mini-implant-supported device, permitting orthopedic expansion with few side effects [1–3]. This procedure is well accepted by patients owing to its low cost and less invasiveness compared to surgically assisted RME [4].

To perform the MARPE technique, cone-beam computed tomography (CBCT) is essential as it allows a complete anatomical evaluation of the nasomaxillary complex

region where the expander screw and mini-implants are placed [5]. Moreover, by assessing bone thickness from CBCT images, the amount of bicortical mini-implant thread insertion can be measured [6]. This is critical as the bicortical positioning of mini-implants permits wider distribution of expansion forces, avoiding the concentration of stress areas around the mini-implants, providing better skeletal effects [7, 8].

Therefore, an evaluation protocol using CBCT [9] was introduced to select the ideal region for the mini-implants. However, this technique does not consider all anatomical variations in each patient, and the lack of a guide that reproduces this planning in the patient's oral cavity is a matter of concern. Thus, André [6] described a technique that performs a careful evaluation of important anatomical structures, such as nasal septum deviation, maxillary sinus extension, the sinuosity of the sutures evaluated, and location of the incisive foramen and transpalatal suture. Although the planning is more comprehensive, there is still a lack of guidance for reproducibility in the oral cavity.

With the advent of digital flow technology, a new technique was introduced, not only for planning, but also to reproduce the virtual placement of the entire appliance, providing accuracy, reproducibility, and safety to the MARPE technique. This technique, called MARPE Guide, consists of a three-dimensional digital placement, which comprises the positioning of the mini-implants specific for MARPE, as well as the expander screw itself. To overcome the shortcomings of the previously described planning techniques, a guide is generated that reproduces this digital placement [5, 10–15].

By superimposing the intraoral digital scanning file (STL) and CBCT (DICOM), it is possible to choose the correct location accurately and safely for the placement of the mini-implants and expander screws. Additionally, the structures of the nasomaxillary complex in a three-dimensional form are individually evaluated (**Figure 1**). Thus, the

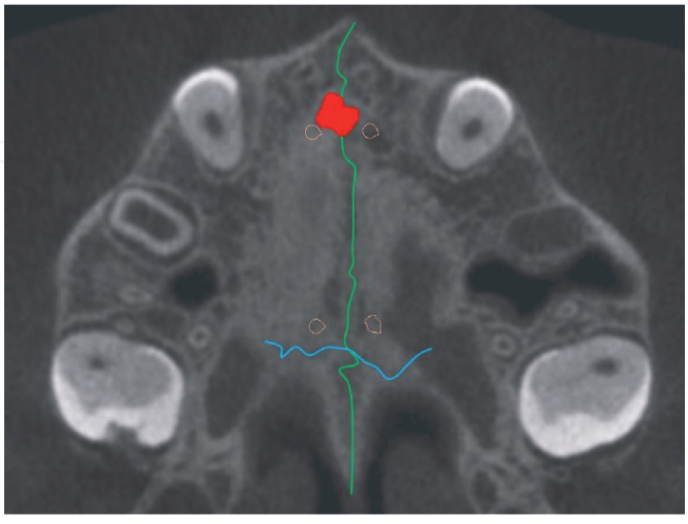

Figure 1.
The image of this case shows a MARPE complex positioning between the incisive foramen and transpalatal suture, not extending to the soft palate area. The midpalatal suture is observed in green, transpalatal suture is represented in blue, nasoapalatine duct is visualized in red, and mini-implants are presented in orange.

chances of failure are reduced using the MARPE guide, as it is possible to select the size and amount of mini-implant thread insertion of each mini-implant. Moreover, it permits accurate prediction of the mini-implant trajectory. Even in the most complex cases of anatomical variations, injury to important anatomical structures is avoided. This increases the safety of the technique, as well as the chances of success. For patients with severe transverse maxillary deficiency, increased palatal depth, or severe asymmetry, the MARPE Guide is associated with a MAEPE model called MARPE EX, developed in 2017 by Peclab (Peclab®, Belo Horizonte, Brazil). This device has an individualized mini-implant ring height, which permits positioning of the MARPE complex without colliding with the lateral palatal soft tissues. Height adjustment is performed according to the anatomy of each patient's palate, even in severe cases of transverse deficiency and maxillary asymmetry [16]. Among the physical characteristics of MARPE EX, the increased distance between the anterior and posterior mini-implant rings is observed, in search of a larger support area for the mini-implants. Regarding the tension exerted by this device on the skull, less tension on the supporting teeth was observed, as well as a wider tension distribution over the entire lateral lamina of the pterygoid process [16].

However, in complex cases of varying thickness of the maxilla and cases of advanced maturation of the midpalatal suture, even with virtual planning, these cases are limited. The increased interdigitation of the midpalatal suture is a strong resistance during RME. Therefore, Suzuki et al. [17] proposed the performance of corticoperforations in the region of the midpalatal suture during RME, to reduce the resistance by weakening the midpalatal suture, relying on the phenomenon of regional acceleration (corticoperforations). Although it appears to be an effective method, it is not a precise procedure as drilling is performed based on the palatal raphe (soft tissue), which does not always coincide with the midpalatal suture itself. Therefore, the Corticoperfuration Guide (Cortex guide) provides the most effective weakening of this suture, enabling guided drilling, performed precisely following its path, that may be sinuous, rectilinear, or curved. Another important and unmentioned factor is perforation along the transpalatal suture. Perforation in the more posterior region is of utmost importance, as the maxillary posterior region demonstrates greater resistance during RME [16, 18].

By adding this new technique of digital planning with the advantages of MARPE EX, treatments are anticipated to become safer, more accurate; thus, expanding the possibility of treatment for patients with severe transverse deficiency, maxillary asymmetry, and variations in the maxillary thickness. Thus, this book chapter proposes the presentation of the virtual MARPE placement as well as the guided corticoperforation technique (Cortex Guide).

2. Materials and methods

2.1 Anatomical evaluation and virtual placement

The analysis of the maturation of facial sutures is performed through the file in DICOM format. For the midpalatal suture, the analysis follows the method proposed by Angelieri et al. [19], where the operator must be calibrated to perform this technique with reproducibility [20]. This technique is critical as an auxiliary diagnostic method, as it provides information regarding the challenge and resistance during the separation of the midpalatal suture according to its maturation stage. Next, another

suture, the zygomaticomaxillary suture, involved in RME is classified (established by Angelieri et al. [21]). This evaluation is performed by accessing the sagittal and coronal sections of the CT scan, and the suture is evaluated in a stage from A to E, where A is the earliest stage of maturation and E is the most advanced stage. The pterygopalatine suture was also evaluated, although there is no consolidated classification in the literature. When it is in an advanced stage of maturation, this suture is quite homogeneous compared to neighboring bone tissues, which is alarming to orthodontists as it suggests greater resistance to RME. Next, the location and shape of the transpalatal suture are analyzed. It is ideal to perform virtual placement of the mini-implants anteriorly to this suture (**Figure 1**); however, in many cases, owing to the positioning of the incisive foramen and reduced anteroposterior dimension of the maxilla, the most anterior virtual placement is not always feasible [5] (**Figure 2**).

In addition to the maturation stage, it is critical to verify the shape and aspect of these sutures as they can be straight, sinuous, or curvilinear. This can occur both horizontally and vertically (observed in coronal and axial sections). This verification is of total importance to perform the virtual placement without touching the sutures (**Figure 3**).

After suture analysis, the three-dimensional files (STL and DICOM, **Figure 4**) were superimposed [10–15]. As described in the literature [5], both files should be of good quality because they provide essential information, such as hard and soft tissue thickness, anatomical variations, and location and trajectory of the mini-implants. Failure to take this information into account may lead to complications and failure of the MARPE technique.

This procedure can be performed in any software that accepts the superimposition of the STL and CBCT files and also permits the importation of mini-implants and the MARPE expander screw-in STL format. This combination allows a three-dimensional

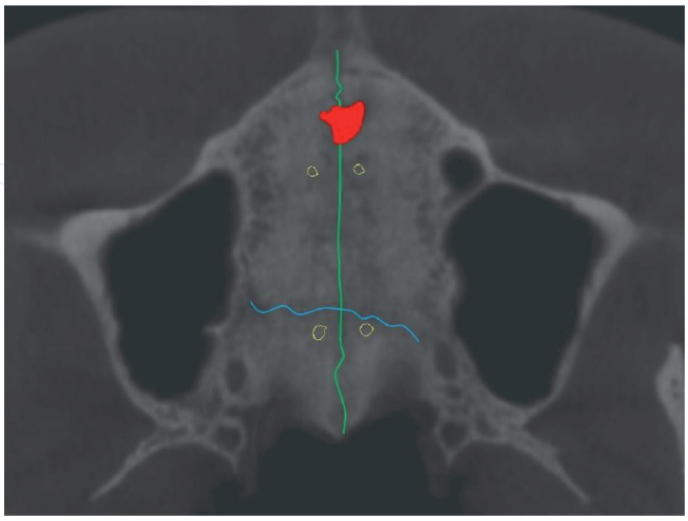

Figure 2.
In this case, the posterior mini-implants could not be placed anterior to the transpalatal suture due to the reduced sagittal size of the maxilla, and the variation in shape and size of the incisive foramen. The midpalatal suture is observed in green, the transpalatal suture is observed in blue, the nasopalatine duct is visualized in red, and mini-implants are presented in red.

Surgical Digitally Guided Planning for the Mini-Screw Assisted Rapid Palatal Expansion...
DOI: http://dx.doi.org/10.5772/intechopen.100226

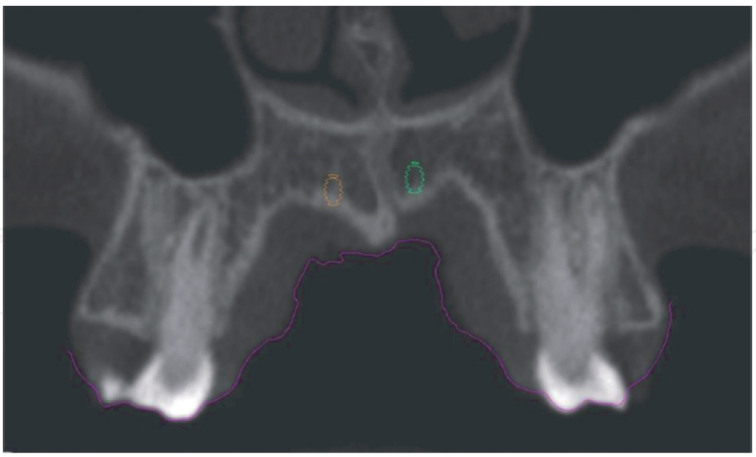

Figure 3.
Anterior mini-implants bordering a sinuous suture, without touching it.

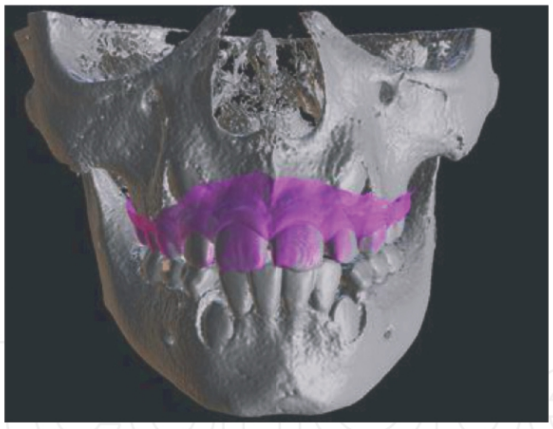

Figure 4.
Superimposition of the CBCT file (DICOM) and the digital file reproducing the teeth and the soft tissue of the upper dental arch (STL).

evaluation of the maxilla; therefore, the orthodontist can evaluate important aspects for the digital positioning of the MARPE device, as it permits simulation of the positioning in different regions.

The ideal region for the mini-implant insertion should contain sufficient bone to perform the expansion, advocating a bicortical positioning [7], as observed in **Figure 5A**. In cases of reduced bone thickness along the maxilla, it is currently feasible to add two more mini-implants to the device [22], as depicted in **Figure 5B**.

After the initial evaluation of the region with the most appropriate bone thickness, a complete anatomical evaluation is initiated, where the location of the midpalatal suture, transpalatal suture, and incisive foramen are first considered.

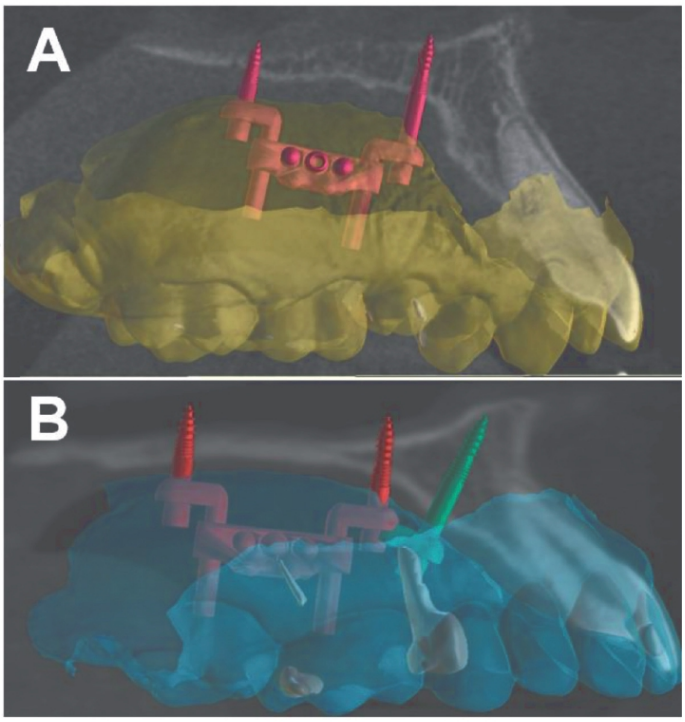

Figure 5.
(A) Bicortical insertion of mini-implants in a patient with good bone thickness. (B) Reduced bone thickness along the entire maxilla, requiring the placement of two additional mini-implants.

These three anatomical components plus adequate bone thickness are the key factors for positioning the EX expander screw and the four or six mini-implants. However, it is critical to observe the distance of this complex from the lateral mucosa to maintain soft tissue integrity during RME.

Anatomical variations are common and must be thoroughly observed when planning the MARPE digital placement such as deviated septum (**Figure 6**), maxillary sinus extension (**Figure 7**), impacted teeth (**Figure 8**), maxillary torus (**Figure 9**), palate depth, and maxillary reduced shape and size (**Figure 7**). For patients with V-shaped palate in the anterior region the digital planning requires a posterior displacement of the appliance for the mini-implant support rings to be well adapted, bicortical, and have an adequate amount of excess mini-implant thread.

Digital placement with MARPE EX permits not only to individualize the height of the mini-implant rings in each region (respecting the anatomy of each individual and a safe distance from the mucosa) but also to measure and place different mini-implant lengths, always preconizing a bicortical positioning [2, 14]. This positioning is verified in each section of the tomography (**Figure 10**) and in the three-dimensional reconstruction.

For more complex cases, such as bone volume variation, advanced age and advanced skeletal maturation, guided corticoperforation is performed. This is done following the anatomy of the midpalatal suture and the transpalatal suture. In some

Surgical Digitally Guided Planning for the Mini-Screw Assisted Rapid Palatal Expansion...
DOI: http://dx.doi.org/10.5772/intechopen.100226

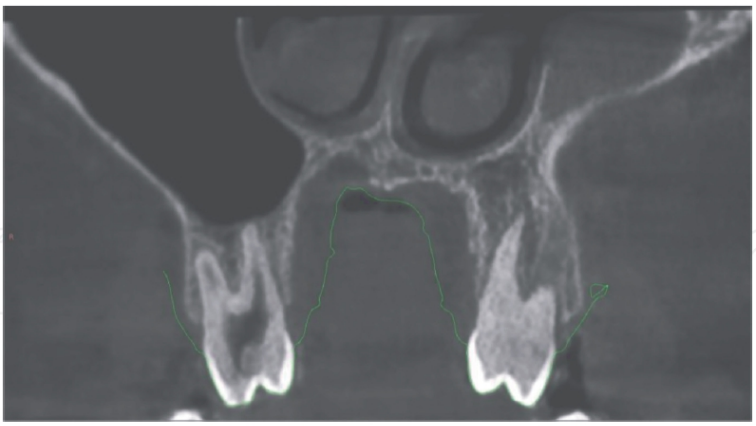

Figure 6.
Nasal septum deviation to the left side of the patient.

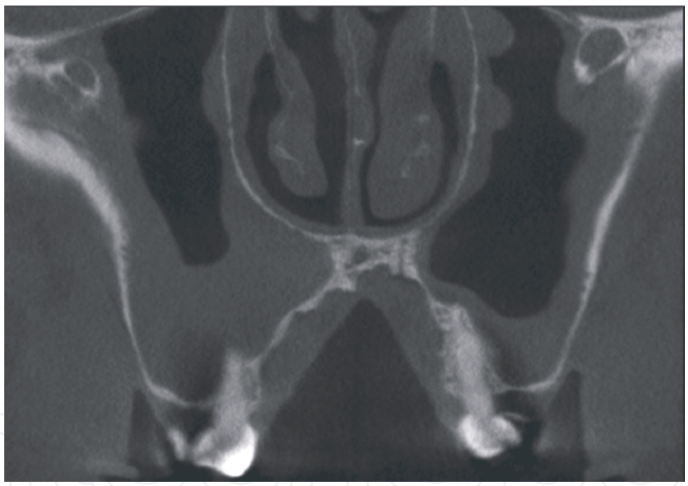

Figure 7.
Alveolar extension of the maxillary sinus and severe transverse deficiency of the maxilla.

patients, the midpalatal suture is inclined and/or sinuous in the coronal direction. We do not use the soft tissue (palatine raphe) as a reference to locate the midpalatal suture, because sometimes they are not coincident (**Figure 11**).

For the simulation of the drilling, we used digital files with a cylindrical format that reproduces the thickness of the widest portion of the drill used. These cylinders are positioned in such a way that they reach bicortical positioning and maintain a uniform distance between them when possible. Each perforation is analyzed in the three-dimensional simulation and checked in each tomography section to ensure that the perforations are bicortical and if there is no collision with important structures such as the nasopalatine duct.

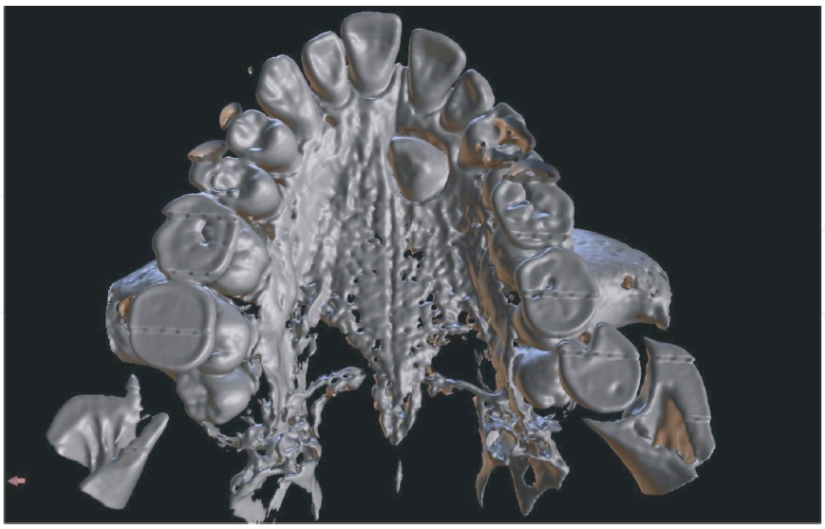

Figure 8.
Impacted tooth in the region near the anterior mini-implant installation placement site.

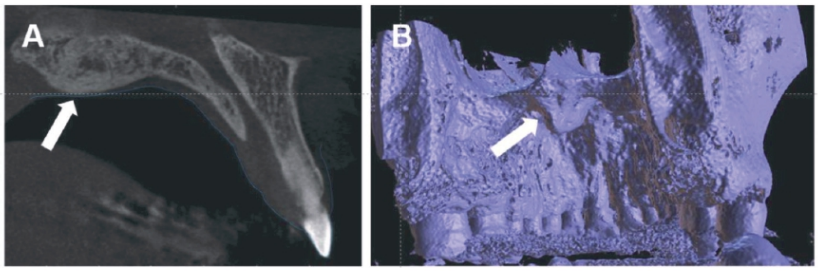

Figure 9.
(A) Sagittal section demonstrating the presence of the palatal torus. (B) Three-dimensional reconstruction of the maxilla illustrating the palatine torus.

When installing drills, we always recommend an inclination that can be performed in the mouth. In this way, we inclined the drills between 10° and 30° with respect to the occlusal plane. The drills are performed precisely following the direction of the suture, either rectilinear or sinuous (**Figure 12**).

It is advisable to maintain a safe distance between the corticoperforation and the region of the MARPE mini-implants as when trying to weaken the suture, we should not weaken the region surrounding the mini-implants, as the tension exerted in this region is high [16] and close perforations can weaken this region, which requires a large bone supply (**Figure 12C**). For this reason, MARPE Guide and Cortex Guide planning should be performed together (**Figure 13**).

After this careful process, it is time to create the guides, which will reproduce both the digital positioning in the prototyped model (MARPE Guide), providing reproducibility to the appliance manufacturing, exactly as done virtually, and the

Surgical Digitally Guided Planning for the Mini-Screw Assisted Rapid Palatal Expansion...
DOI: http://dx.doi.org/10.5772/intechopen.100226

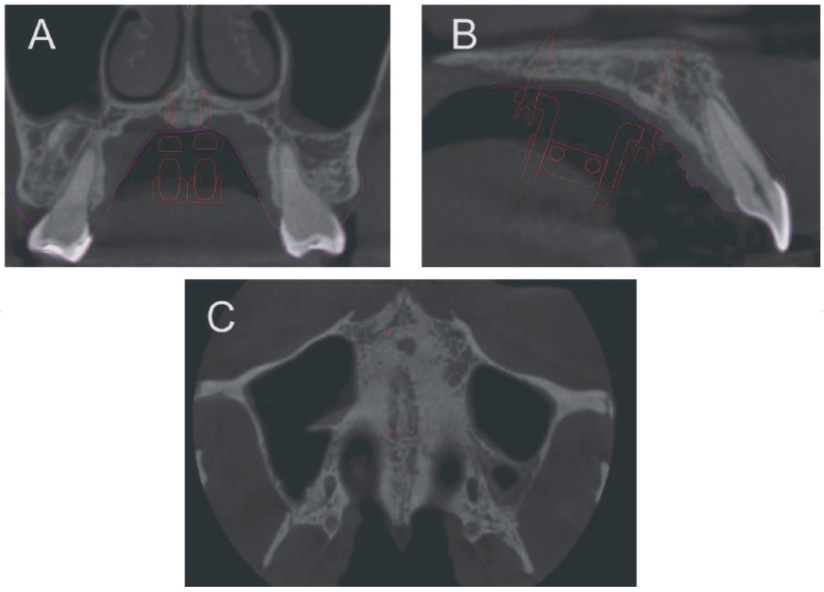

Figure 10.
(A) Coronal section, illustrating the digital placement of MARPE, even in cases of severe atresia and asymmetry. (B) Sagittal section, showing the bicortical position of the mini-implants, respecting a discrete distance from the mucosa to avoid collision during expansion. (C) Placement of the mini-implants, respecting the midpalatal suture, as well as the transpalatal suture and the incisive foramen.

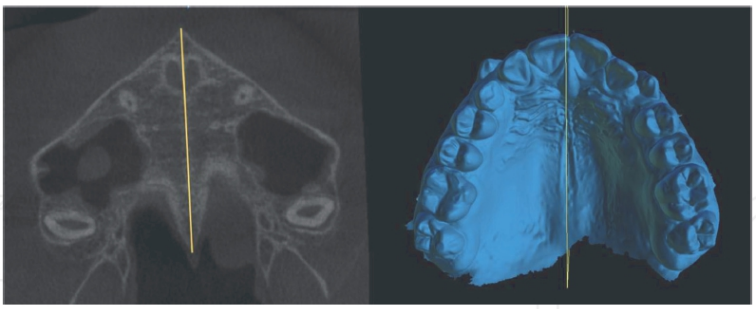

Figure 11.
Palatal raphe and midpalatal suture are not coincident. If the corticoperfortaion is not performed in a guided way. It can lead to an error during the procedure.

corticoperforation guide (Cortex Guide), which reproduces the digital perforation of each point created, with angulation and insertion limits.

2.2 Presentation of a complete planning

Below, we present a complete MARPE Guide and Cortex Guide planning, following all the parameters discussed above (**Figures 14–19**).

Subsequently, the MARPE guide and cortex guide are made as detailed above.

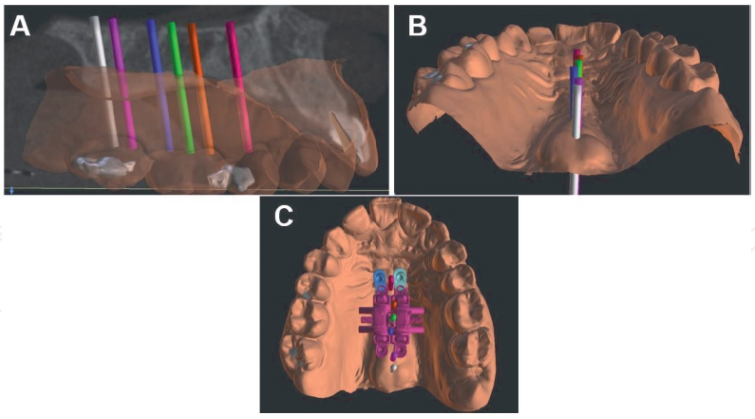

Figure 12.
(A) Perforations performed with bicortical positioning. (B) Note that the positioning respects the suture inclination in both coronal and axial directions. (C) The perforations are performed preserving bone tissue around the MARPE mini-implants.

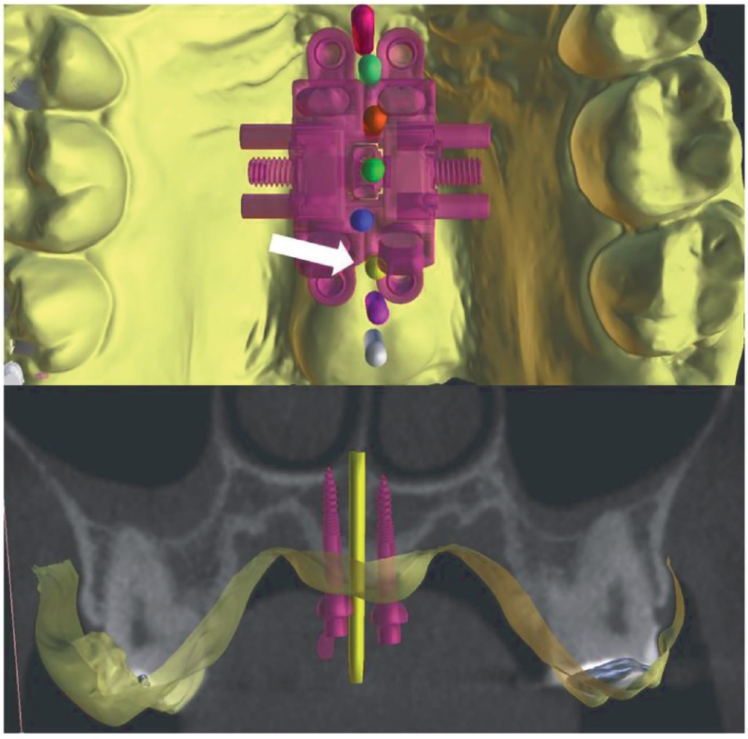

Figure 13.
In the top image we see the simulations of the corticoperforations that would be ideal for this case. However, in the bottom image we note that the perforation in yellow is very close to the posterior mini-implants, which could compromise the technique.

Surgical Digitally Guided Planning for the Mini-Screw Assisted Rapid Palatal Expansion...
DOI: http://dx.doi.org/10.5772/intechopen.100226

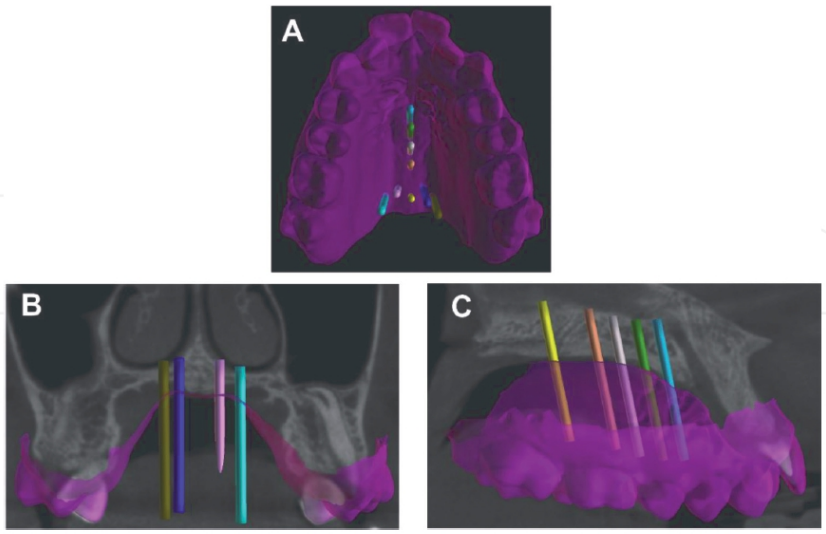

Figure 14.
(A) Virtual corticoperforation drills installed in the midpalatal suture and transpalatal suture. (B) Coronal view (transpalatal suture). (C) Lateral view in sagittal section (midpalatal suture).

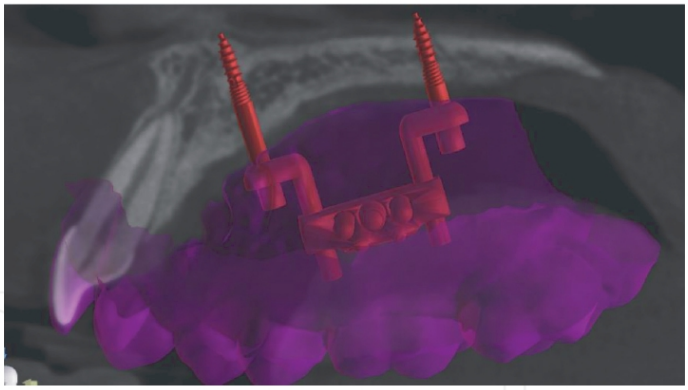

Figure 15.
Sagittal section of the tomography – left side. MARPE installed respecting the bicortical positioning and with the distance of the mini-implant rings from the mucosa.

2.3 MARPE guide

For the virtual placement of MARPE, a concern about injuries caused to the soft tissue due to the contact of the mini-implant rings is resolved with the digital placement (with the MARPE EX and MARPE guide). It has an internal stop that accommodates each mini-implant support ring (**Figure 20**), and its height is established according to the individual's anatomy. It is important to keep the expander screw body as horizontal as possible (**Figure 21**) in the coronal section of the tomography without touching the lateral mucosa.

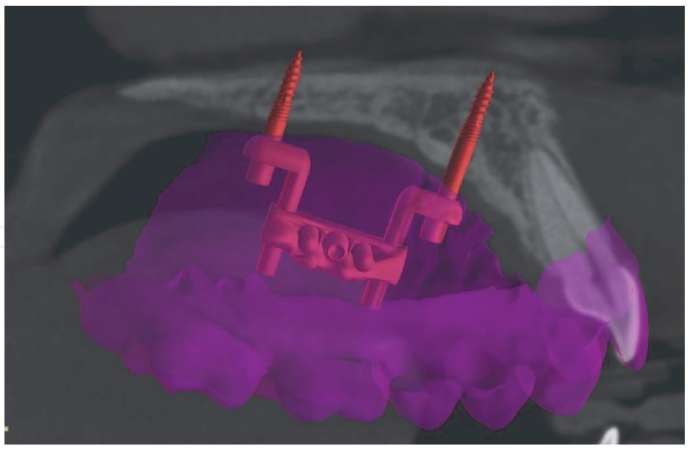

Figure 16.
Sagittal section of the CT scan – left side.

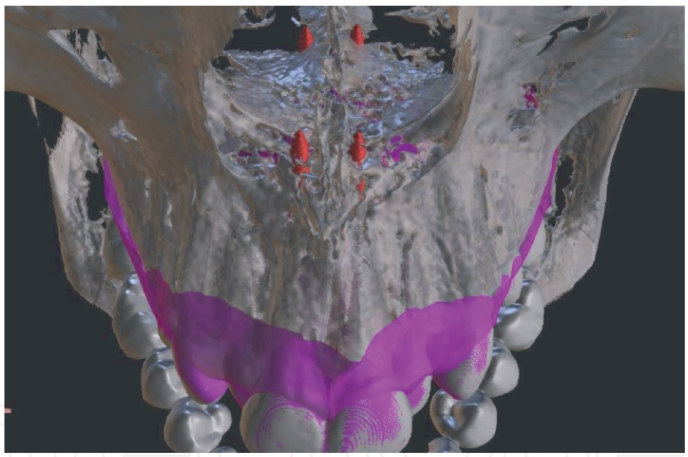

Figure 17.
3D reconstruction of the CT scan illustrating a safe distance of the mini-implants from the transpalatal suture. Note the bicortical positioning of the four mini-implants.

We should be aware of the occlusal plane and nasal floor inclination, which, when altered, can cause asymmetry in the patient. Thus, a stop that holds the expander screw body in position is necessary (**Figure 21**). This guide design is inserted into the patient's STL file, so they are printed at once, which reduces the chances of error by overlapping the guide to the patient's model, in addition to saving printed material.

2.4 Corticoperforation guide

The corticoperforation guide, requires a retentive design (that embraces the posterior teeth), as it will be adapted in the mouth, as a positioner and vertical limiter of each perforation (**Figure 22**) and must remain stable during the process.

Surgical Digitally Guided Planning for the Mini-Screw Assisted Rapid Palatal Expansion...
DOI: http://dx.doi.org/10.5772/intechopen.100226

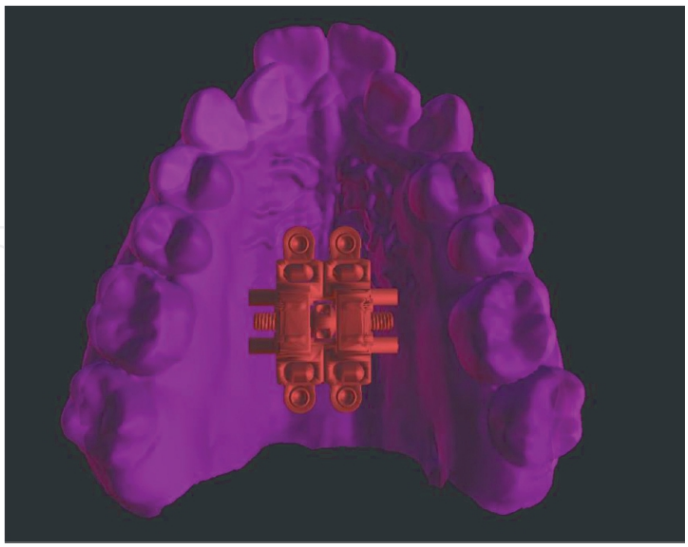

Figure 18.
Occlusal view of the virtually installed MARPE, preserving the lateral tissue and soft palate.

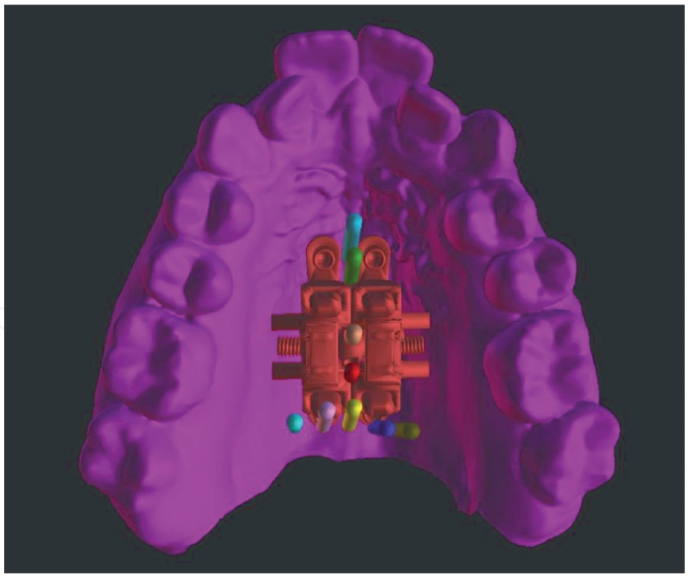

Figure 19.
MARPE guide and cortex guide in the same image to check if there is any collision between the digital plans, such as drilling too close to a mini-implant.

2.5 Laboratory phase – printing the MARPE guide and cortex guide

Finally, it is possible to fabricate MARPE with the reproducibility of each of the precautions taken during the virtual placement. The MARPE EX is made on the guide

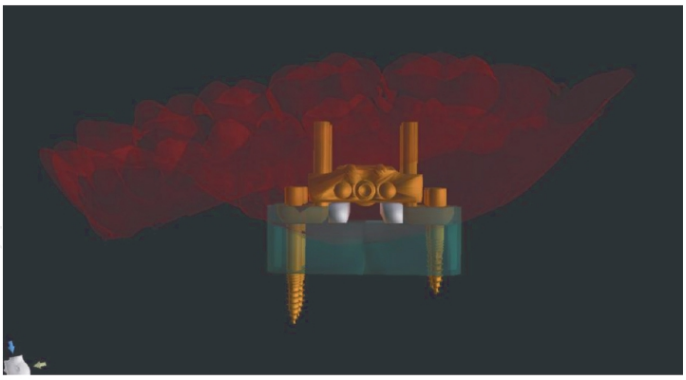

Figure 20.
In green we see the MARPE guide, which accommodates the adjustable mini-implant rings of the MARPE EX, to reproduce the positioning performed during the virtual placement.

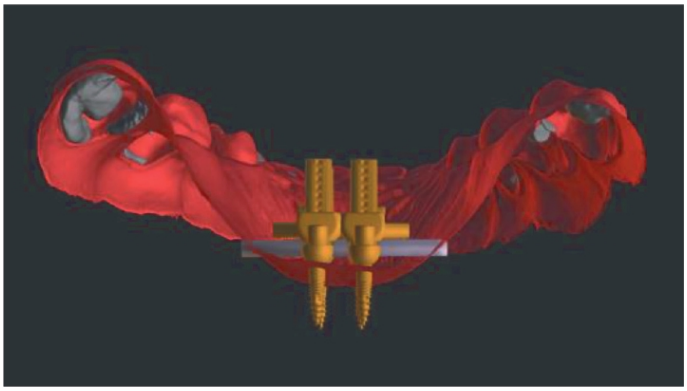

Figure 21.
Digital horizontal support (gray) that are responsible for keeping the MARPE appliance at the planned height during the virtual placement, so that the expander screw does not touch the soft tissue and mainly, remains as horizontal as possible, preventing it from causing any asymmetry in the patient.

template (**Figure 23**), where its mini-implant rings fit exactly inside each small guide, which eliminates transfer errors. It also determines the height and inclination of the expander screw, preventing asymmetries during expansion. Using laser welding, it is possible to weld the MARPE EX to the bands without damaging the prototype model or causing any swelling of the metal of the MARPE EX, owing to the heat of the formerly used silver-based welds.

After this phase, the appliance is polished, and it is ready to reproduce with accuracy the digital planning in the oral cavity. Note that the guide is not used in the oral cavity; it serves as a guide for fabricating the appliance. In the oral cavity the guide for cementation is the bands on the first permanent molars.

To reproduce the corticoperforations in the oral cavity, after designing the guide, it is critical to make an impression of the guide in biocompatible resin (**Figure 24**), and this protocol must be followed even if the guide remains in the oral cavity for some time.



Figure 22.
3D planning of the corticoperforation guide, which reproduces the angulation of each perforation, following the midpalatal suture and transpalatal suture. This guide will also be the limiter for the drill cutter, as soon as it touches the guide, the clinician will know that it has reached the nasal floor cortical.

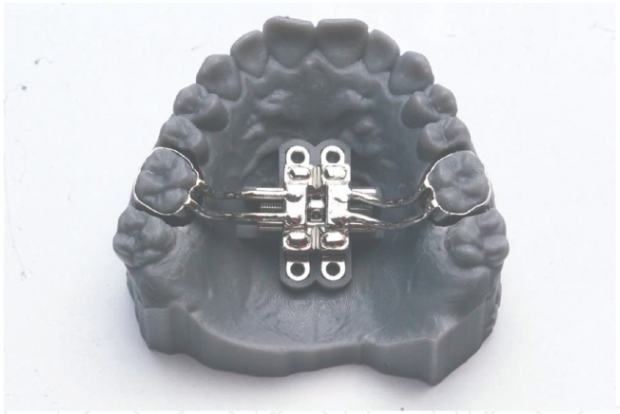

Figure 23.
MARPE device built over the printed MARPE guide template.

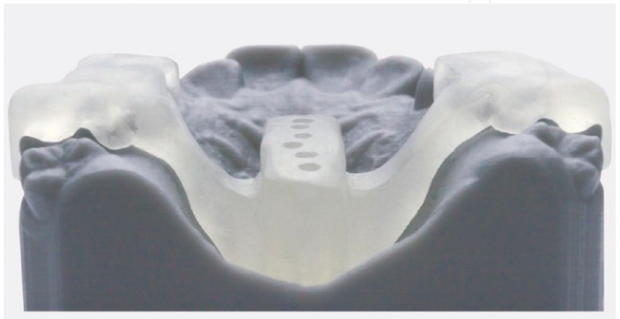

Figure 24.
Cortex guide printed in biocompatible resin.

3. Discussion

For a very short time, the MARPE technique was performed without CT scanning. This type of treatment required three-dimensional (3D) planning since the maxilla contains important structures that must be preserved, both for the patient's safety and success of the technique. The first safety protocols were based on bone and mucosa thickness measurements in the region of first premolars, second premolars, first molars, and second molars [6, 9]. Despite providing important information, these protocols did not show the exact trajectory of MARPE mini-implants. Moreover, the standardization of the patient's head position and evaluation of the tomography sections could not be faithfully reproduced in the oral cavity. This necessitated the creation of digital positioning guides [10–13]. In cases of severe transverse deficiency of the maxilla or asymmetry [23], devices such as the MARPE maxillary skeletal expansion (MARPE MSE) or MARPE SL cannot be indicated because the expander screw does not fit in the palate (**Figure 25**).

Thus, the present study proposes the development of a guide for planning the MARPE technique using MARPE EX [5, 16], to evaluate the capacity of this guide in performing an ideal positioning of the MARPE, prioritizing the adaptation of the mini-implant rings, and respecting the individual anatomy of the patient's palate. The distance between the mini-implants is higher in MARPE EX than that of the other models of MARPE, which, according to a previous study [16], was favorable for better results. Another advantage is that MARPE EX accepts this guide model, where we can place the mini-implant rings away from the palate at customized heights according to the patient's anatomy. This distance from the palate in its closest region is approximately 0.2 mm, both towards the palate (vertical) and towards the lateral mucosa (horizontal) [5]. Therefore, no ring juxtaposed should be left juxtaposed to the tissues.

The EX model was also chosen because it demonstrated less tension in the teeth and mini-implants during RME [16], and it presented more tension, with wide distribution, in the lateral lamina of the pterygoid process [16]. According to Brunetto et al. [18], the lateral lamina of the pterygoid process offers the greatest resistance during

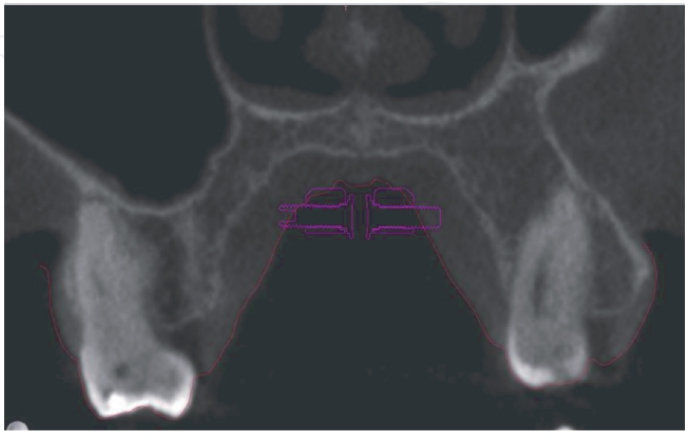

Figure 25.
Model of MARPE without adjustable mini-implant rings. This figure shows that without adjustable mini-implant rings the MARPE does not fit patients with severe transverse disability.

RME. Recent clinical studies have shown that bicortical directly influence treatment with MARPE [8, 24], particularly in patients with advanced maturation stage sutures as the bicortical positioning of mini-implants permits the separation of even the most posterior sutures, such as the lateral lamina from the medial lamina of the pterygoid process [8]. Thus, this demonstrates the importance of a guide that correctly reproduces this bicorticality in the patient, such as the MARPE Guide. It is also important to recognize the importance of the bands, which, in addition to distributing stress, are responsible for transferring the guide model to the oral cavity.

The three initial parameters for placing an MARPE must be discussed. First, it should not touch the midpalatal and transpalatal sutures; second, it should be distant from the incisive foramen; and third, preferably anterior to the transpalatal suture, avoiding collision/perforation of the mini-implants with sutures. We should not touch the incisive foramen to avoid contact with the nerve of the incisive canal, which can result in anterior maxillary paresthesia.

The location of the transpalatal suture does not always coincide with the soft palate; however, if it does, we avoid placing it posteriorly to the transpalatal suture, so that the mini-implants are not inserted in a region of free mucosa, with more chances of inflammation, great difficulty in cleaning, and loss of the mini-implants. However, in some cases of the reduced anteroposterior distance of the maxilla, this becomes unavoidable. The patient's anatomical variation should be considered as it influences the results, such as mini-implants placed in the nasal septum in a patient with palate asymmetry [25] and resulting in a unilateral opening [25]. This highlights the importance of using 3D planning, where insertion in the septum can be easily avoided and bilateral opening can be achieved, eliminating side effects.

While dealing with anatomical variations, it is common to find patients with variations in maxillary sinus extension (**Figure 7**). If the mini-implants are inserted into the sinus cavity, in addition to creating an oral-sinus communication that can generate pain, inflammation, and discomfort, this is a region without trabecular bone, that is, a region that lacks bone volume. Therefore, mini-implants cannot withstand the tension exerted during maxillary expansion [16].

Corticoperforation can be indicated when a torus palatine (**Figure 9**) is detected as it has the potential to decrease the chances of success. Guided corticoperforation, besides allowing perforation of the transpalatal suture, provides accuracy due to the angulation of the guide, which was determined in the virtual simulation, leaving the patient free of perforations outside the suture. Corticoperforations oriented by the palatine raphe may cause asymmetric fractures or even case failure because if performed too close to the mini-implant placement site, they reduce the bone volume required for the tension exerted in the mini-implant region [16]. Another risk of not virtually simulating the corticoperforations and creating a stop guide is to over drill the nasal cavity floor, causing pain to the patient and a bucco-nasal communication, which may lead to sinusitis; in case of inflammation, possibly worsening to bone necrosis or osteomyelitis.

4. Conclusions

The two-dimensional plans do not predict the mini-implant trajectory, and the choice of the mini-implant can be highly subjective and susceptible to errors. The use of the MARPE Guide has already presented interesting results in the literature. By combining the benefits of the MARPE Guide with the MARPE EX and the use of the

Cortex Guide, virtual placement may be performed in a patient with palate asymmetry, bone volume variation, and advanced stage of midpalatal suture classification. This results in tension in the lateral lamina considering the patient's anatomy. Clinical studies are needed to evaluate the results of this new technique in a considerable number of patients.

Conflict of interest

The authors declare no conflict of interest.

Author details

Cristiane Barros André[1*], Bruno de Paula Machado Pasqua[2], José Rino Neto[2] and Fábio Dupart Nascimento[1]

1 Technology Research Center, University of Mogi das Cruzes, Mogi das Cruzes, Brazil

2 School of Orthodontics, University of São Paulo, São Paulo, Brazil

*Address all correspondence to: kika@kikaortodontia.com.br

IntechOpen

© 2021 The Author(s). Licensee IntechOpen. This chapter is distributed under the terms of the Creative Commons Attribution License (http://creativecommons.org/licenses/by/3.0), which permits unrestricted use, distribution, and reproduction in any medium, provided the original work is properly cited.

References

[1] Lee KJ, Park YC, Park JY, Hwang WS. Mini-implants-assisted nonsurgical palatal expansion before orthognathic surgery for a patient with severe mandibular prognathism. Am J Orthod Dentofacial Orthop 2010;(138): 830-839.

[2] Cantarella D, Dominguez-Mompell R, Moschik C, et al. Midfacial changes in the coronal plane induced by micro-implant-supported skeletal expander, studied with cone-beam computed tomography images. Am J Orthod Dentofac Orthop 2018;154(3):337-345.

[3] Celenk-Koca T, Erdinc AE, Hazar S, Harris L, English JD, Akyalcin S. Evaluation of mini-implants-supported rapid maxillary expansion in adolescents: A prospective randomized clinical trial. Angle Orthod 2018;(88):702-709.

[4] Stuart DA, Wiltshire WA. Rapid palatal expansion in the young adult: Time for a paradigm shift? J Can Dent Assoc 2003;(69):374-377.

[5] André CB. MARPE guide: from consolidation to technique evolution. Clin Orthod 2020;19(5):00-00.

[6] André CB. Análise tomográfica para técnica Marpe. Rev Clin Ortod Dental Press 2018;17(4):50-53.

[7] Lee RJ, Moon W, Hong C. Effects of monocortical and bicortical micro-implant anchorage on bone-borne palatal expansion using finite element analysis. Am J Orthod Dentofac Orthop 2017;151(5):887-897.

[8] Li N, Sun W, Li Q, Dong W, Martin D, Guo J. Skeletal effects of monocortical and bicortical mini-implant anchorage on maxillary expansion using cone-beam computed tomography in young adults. Am J Orthod Dentofacial Orthop 2020;157(5):651-661.

[9] Nojima LI, Nojima M, Cunha ACD, Guss NO, Sant'Anna EF. Mini-implant selection protocol applied to MARPE. Dental Press J Orthod 2018;23(5):93-101.

[10] Maino BG, Paoletto E, Lombardo L, Siciliani G. A three-dimensional digital insertion guide for palatal micro-implant placement. J Clin Orthod 2016;50(1): 12-22.

[11] De Gabriele O, Dallatana G, Riva R, Vasudavan S, Wilmes B. The easy driver for placement of palatal micro-implants and a maxillary expander in a single appointment. J Clin Orthod 2017;51(11): 728-737.

[12] André CB. Instalação virtual dos aparelhos: para que serve? Rev Clin Ortod Dental Press 2019;18(5):52-58.

[13] Lombardo L, Occhiuto G, Paoletto E, Maino BG, SIiciliani G. Class II treatment by palatal mini-implants-system appliance: A case report. Angle Orthod 2019;90(2):305-313.

[14] Antonino Lo Giudice, Vincenzo Quinzi, Vincenzo Ronsivalle, Stefano Martina, Orazio Bennici, and Gaetano Isola. Description of a digital work-flow for CBCT-guided construction of micro-implant supported maxillary skeletal expander. Materials 2020(13):1815.

[15] Cantarella D, Savio G, Grigolato L, Zanata P, Berveglieri C, Lo Giudice A, Isola G, Del Fabbro M, Moon W. A new methodology for the digital planning of micro-implant-supported maxillary skeletal expansion. Med. Devices Evid. Res. 2020;13:93-106.

[16] André CB, Rino-Neto J, Iared W, et al. Stress distribution and displacement of three different types of micro-implant assisted rapid maxillary expansion (MARME): A three-dimensional finite element study. Prog Orthod 2021; 22:20.

[17] Suzuki SS, Garcez AS, Reese PO, Suzuki H, Ribeiro MS, Moon W. Effects of corticopuncture (CP) and low-level laser therapy (LLLT) on the rate of tooth movement and root resorption in rats using micro-CT evaluation. Laser Med Sci 2018;33(4):811-821.

[18] Brunetto DP, Sant'Anna EF, Machado AW, Moon W. Non-surgical treatment of transverse deficiency in adults using microimplant-assisted rapid palatal expansion (MARPE). Dental Press J Orthod 2017;22(1):110-125.

[19] Angelieri F, Franchi L, Cevidanes LHS, Toyama-Hino C, Nguyen T, McNamara JA Jr. Zygomaticomaxillary suture maturation: A predictor of maxillary protraction? Part I: Classification method. Orthod Craniofac Res 2017;(20):85-94.

[20] Barbosa NMV, Castro AN, Conti F, Capelozza-Filho L, Almeida-Pedrin RR, Cardoso MA. Reliability and reproducibility of the method of assessment of midpalatal suture maturation: A tomographic study. Angle Orthod 2019;89(1):71-77.

[21] Angelieri F, Franchi L, Cevidanes LHS, Hino CT, Nguyen T, McNamara Jr JA. Zygomaticomaxillary suture maturation: A predictor of maxillary protraction? Part I – A classification method. Orthod Craniofac Res 2017;20(2):85-94.

[22] Cury SEN, Mondelli AL, André CB, Iared W, Guerra JGP, Rovira J, Berni L. Protocolo diferencial para a técnica MARPE em pacientes com variação no volume ósseo do palato. Rev Clín Ortod Dental Press 2019;18(4): 116-129.

[23] Andrade T. MARPE: uma alternativa não cirúrgica para o manejo ortopédico da maxila – parte 2. Rev Clín Ortod Dental Press 2019;17(6):24-41.

[24] Moon HW, Kim, MJ, Ahn, HW, Kim, SJ, Kim, SH, Chung, KR, Nelson, G. Molar inclination and surrounding alveolar bone change relative to the design of bone-borne maxillary expanders: A CBCT study. Angle Orthod 2020;90(1):13-22.

[25] Santos AM, Miranda F, Rocha AD, Cruz AP, Naveda R, Garib D. Mini-implants-assisted rapid palatal expansion in adult patient with severe maxillary constriction: Case report. Clin Orthod 2021;19(6):101-112.

4.3.3 Miniscrew-assisted rapid palatal expansion (MARPE): factors influencing planning

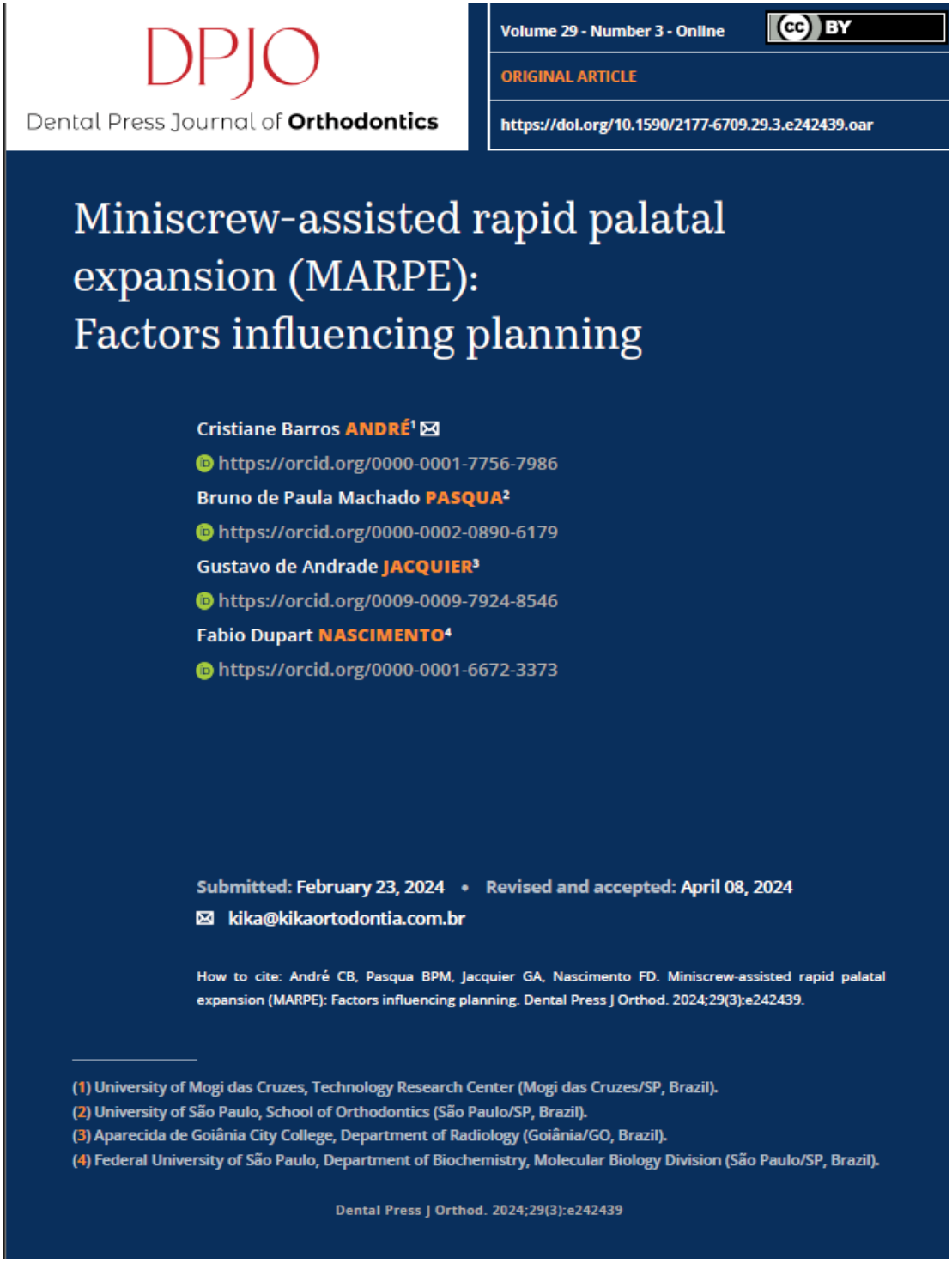

DPJO
Dental Press Journal of Orthodontics

Volume 29 - Number 3 - Online

ORIGINAL ARTICLE

https://doi.org/10.1590/2177-6709.29.3.e242439.oar

Miniscrew-assisted rapid palatal expansion (MARPE): Factors influencing planning

Cristiane Barros ANDRÉ[1] ✉
https://orcid.org/0000-0001-7756-7986
Bruno de Paula Machado PASQUA[2]
https://orcid.org/0000-0002-0890-6179
Gustavo de Andrade JACQUIER[3]
https://orcid.org/0009-0009-7924-8546
Fabio Dupart NASCIMENTO[4]
https://orcid.org/0000-0001-6672-3373

Submitted: February 23, 2024 • Revised and accepted: April 08, 2024

✉ kika@kikaortodontia.com.br

How to cite: André CB, Pasqua BPM, Jacquier GA, Nascimento FD. Miniscrew-assisted rapid palatal expansion (MARPE): Factors influencing planning. Dental Press J Orthod. 2024;29(3):e242439.

(1) University of Mogi das Cruzes, Technology Research Center (Mogi das Cruzes/SP, Brazil).
(2) University of São Paulo, School of Orthodontics (São Paulo/SP, Brazil).
(3) Aparecida de Goiânia City College, Department of Radiology (Goiânia/GO, Brazil).
(4) Federal University of São Paulo, Department of Biochemistry, Molecular Biology Division (São Paulo/SP, Brazil).

ABSTRACT

Objective: This cross-sectional study evaluated the bone thickness on mini-implants insertion site, the factors that influence the digital planning of MARPE appliance (miniscrew-assisted rapid palatal expansion), and its different designs.

Methods: A total of 135 plannings were assessed regarding the size of the expander screw used, the positioning and the type of the mini-implant rings, and their location in relation to the teeth. Bone thickness measurements were assessed in the region of the mini-implants' trajectory. Differences between the sexes was verified using the ANOVA test (5% significance).

Results: 73 cases were planned with 4 mini-implants and 62 cases, with 6 mini-implants. In 90% of cases, teeth #16 and #26 were used as supports, and the most used expander screw was 13mm (64.1% of cases). The anterior mini-implants of conventional MARPE showed more pronounced insertion in bone in males (5.9 ± 2mm; p= 0.025). The extra mini-implants (anterior region) were inserted with greater bone thickness in males (11.1 ± 2.3mm) compared to females (9.9 ± 1.8mm; p=0.041). A greater bone thickness was observed in males (10.1 ± 2.1 mm) when using mini-implants in the paramedian region.

Conclusion: Additional rings allow more pronounced bone insertion. Male patients had greater bone thickness, which may be related to greater difficulty in opening the sutures. The alveolar process region seems to be a satisfactory site for mini-implants to those patients with reduced bone thickness in the paramedian posterior region. MARPE appliance must be customized for each patient, due to bone thickness and anatomical variations.

Keywords: Cone-beam computed tomography. Orthodontic anchorage procedures. Orthodontic appliances, fixed. Orthodontic appliance design.

RESUMO

Objetivo: Avaliar os fatores que influenciam o planejamento digital do expansor MARPE (*miniscrew-assisted rapid palatal expansion*), a espessura óssea no local de inserção dos mini-implantes, e os diferentes possíveis desenhos desse aparelho.

Métodos: Foram avaliados 135 planejamentos quanto ao tamanho do parafuso expansor utilizado, posicionamento, tipo dos anéis dos mini-implantes, e sua localização em relação aos dentes de apoio. As medidas de espessura óssea foram avaliadas na região de inserção dos mini-implantes. As diferenças entre os sexos foram verificadas por meio do teste ANOVA (5% de significância).

Resultados: Os planejamentos tiveram uma distribuição de 73 casos com quatro mini-implantes e 62 casos com seis mini-implantes. Em 90% dos casos, os dentes #16 e #26 foram usados como dentes de apoio, e o parafuso expansor mais usado foi o de 13 mm (64,1% dos casos). Os mini-implantes anteriores do MARPE convencional mostraram uma inserção com maior espessura óssea em homens (5,9 ± 2mm; p= 0,025). Os mini-implantes extras (região anterior) foram inseridos com maior espessura óssea nos homens (11,1 ± 2,3 mm), em comparação com as mulheres (9,9 ± 1,8 mm; p=0,041). Foi observada maior espessura óssea em homens (10,1 ± 2,1 mm) na região paramediana.

Conclusões: Anéis adicionais permitem uma inserção óssea mais pronunciada. Os pacientes do sexo masculino apresentaram maior espessura óssea, o que pode estar relacionado à maior dificuldade de abertura das suturas.

Palavras-chave: Tomografia computorizada de feixe cônico. Procedimentos de ancoragem ortodôntica. Aparelhos ortodônticos. Fixo. Design de aparelhos ortodônticos.

INTRODUCTION

Miniscrew-assisted rapid palatal expansion (MARPE) is a technique performed in adults with transverse maxillary deficiency in an outpatient setting. This appliance is industrialized, and variations in design occur only by changing its anteroposterior positioning.[1]

However, for patients with anatomical variations, such as a deviated septum, bone failures, alveolar extension of the maxillary sinus, enlarged nasopalatine duct, sinuous sutures, and even a lack of space in the maxilla, customized appliance design and three-dimensional planning are necessary.[2,3] This digital planning includes the virtual installation of the MARPE and mini-implants, which is performed using tomographic images superimposed on the intraoral scan.[3] Moreover, this technique provides the means to use segmented appliances, that is, it allows assembling them in individual parts, respecting possible anatomical variations in each patient. Therefore, the expander screw and mini-implant rings (with holes for inserting the mini-implants) are installed virtually, and are responsible for reproducing the digital planning in the oral cavity, and guiding the placement of mini-implants. This versatility allows the addition of more mini-implants to conventional MARPE, such as in cases of reduced bone thickness.[4]

A detailed and in-depth anatomical analysis revealed the need for new resources, such as the use of mini-implants in the alveolar process region.[5] Although the paramedian region generally has sufficient available bone,[6] the posterior maxilla often has reduced bone thickness, which prevents adequate bone support. Hence, the possibility of using MARPE has expanded even in patients with mutilations or reduced bone volume in the parasutural region.

Virtual placement and new customization options for MARPE have recently emerged, aiming to increase case predictability and safety. As these are recent tools, the present cross-sectional study used tomography and intraoral scanning to evaluate the factors that influence MARPE planning and different possible designs of this appliance.

MATERIAL AND METHODS

STUDY DESIGN

This cross-sectional study analyzed the variations in MARPE designs by the assessment of 135 treatment plans of patients with a median age of 27.3 years (10.8–59.5) of both sexes.

ETHICAL APPROVAL

This study was approved by the Ethics Committee of the University of Mogi da Cruzes (CAAE: 55356821.1.0000.5497; approval number: 5.360.812). Informed consent was not required because all cone-beam computed tomography (CBCT) images were obtained in the past and used for MARPE planning — which are part of an existing database (Kika Digital Orthodontics Company, Brazil). All data were anonymized before the investigation.

INCLUSION AND EXCLUSION CRITERIA

The inclusion criteria were: patients of both sexes, with a transverse maxillary deficiency, aged between 10 and 59 years, with CBCT scans performed between October 2022 and June 2023. The exclusion criteria were: CBCT scans of patients with nasopalatine clefts, syndromes, and craniofacial malformations.

MEASUREMENTS

The CBCT scans were previously obtained using an iCAT equipment (Imaging Sciences International, Hatfield, Pennsylvania) with the following settings: 120 kVp, 18 mA; exposure time = 8.9 s; voxel size = 0.2 mm; and a field of view = 160 × 60 mm.

VARIABLES EVALUATED

A total of 135 plans were evaluated to collect data on the prevalence of expander screw sizes used, the positioning and type of mini-implant rings, bone thickness at mini-implant trajectory, their location in relation to the teeth and transverse palatine suture, the positioning of the mini-implants in relation to the palatal rugae, and their cortical positioning (Fig. 1). The specific points for measuring bone thickness involved identifying the limits of mini-implant insertion along its trajectory, precisely at the midpoint of the implant (Fig. 2). All measurements were conducted by a single operator, calibrated to ensure impartiality and accuracy.

Industrialized MARPE appliances have four rings that guide the mini-implant insertion. These rings are round and smooth inside, and a specific mini-implant for the MARPE technique is inserted after the appliance has been cemented (Fig. 3). These rings do not keep the mini-implant locked to the appliance in sagittal mechanics, as in cases of MARPE associated with reverse traction of the maxilla or distalization of the posterior teeth. This is because if the banded teeth are moved anteroposteriorly, the appliance can move until it compresses the palatal mucosa.

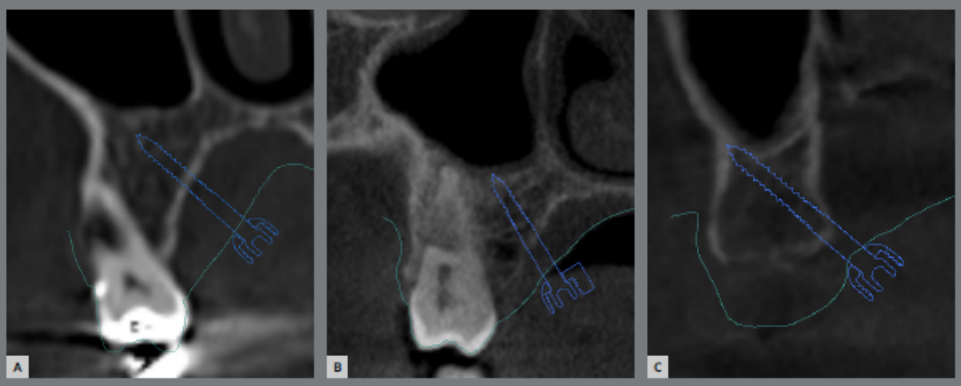

Figure 1: A) Monocortical, **B)** bicortical, and **C)** tricortical positioning.



Figure 2: Bone thickness measurement at mini-implant trajectory: **A)** paramedian region (sagittal section), **B)** alveolar bone region (parasagittal section).

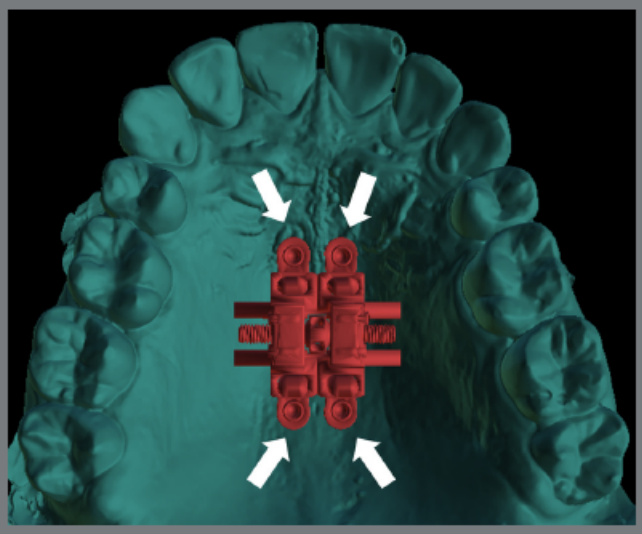

Figure 3: Conventional miniscrew-assisted rapid palatal expansion (MARPE). Note the mini-implants inserted into the rings of this prefabricated appliance.

To solve this problem and broaden the range of biomechanical options, the skeletal ring was developed (PecLab, Belo Horizonte, Brazil), which differs from the conventional ring (hole) due to the internal thread that, after cementing the appliance and placing the mini-implant, receives a lid also with a thread, which guarantees the stability of the appliance for any movement made (Fig 4). The skeletal ring is also planned in the alveolar process in cases where there is reduced bone thickness in the posterior paramedian region (Fig 5).

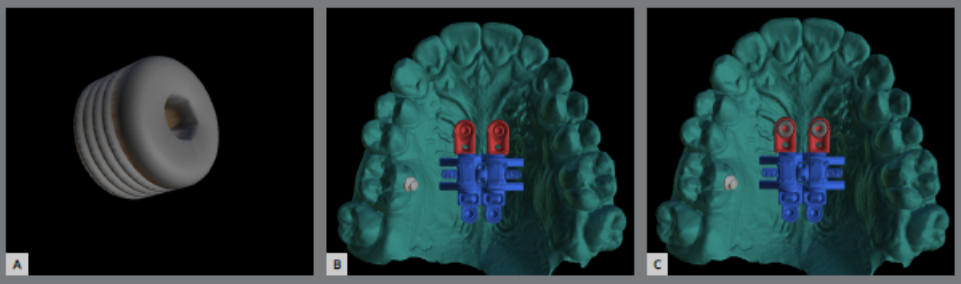

Figure 4: A) Lid of the skeletal ring, which locks the mini-implant to the device. Skeletal ring (red) with mini-implants inserted in the anterior region without the lid (**B**), and with the lid (**C**).

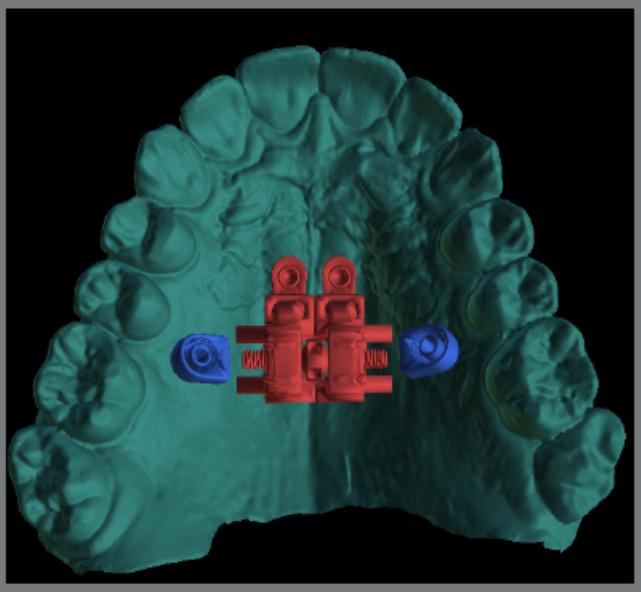

Figure 5: Skeletal rings in the alveolar region.

Considering other possible MARPE designs, the paramedian region presents four planning options:

1) Four mini-implants from the appliance itself (conventional MARPE, Fig. 3).
2) Four or six mini-implants, two or four from the appliance itself, and two conventional extras (without internal threads) (Fig. 6).
3) Two extra mini-implants in the skeletal rings (with an internal thread) (Fig. 4).
4) Two extra mini-implants in skeletal rings in the anterior region, and two in the posterior region (alveolar process bone) (Fig. 7).

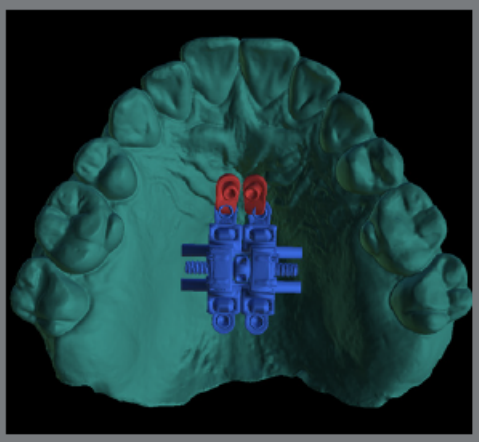

Figure 6: Anterior extra rings.

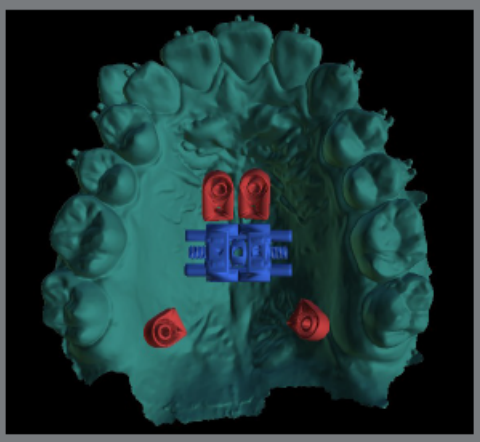

Figure 7: Skeletal rings in the paramedian and alveolar process regions.

CBCT MEASUREMENTS

The bone thickness was measured in the region of the mini-implant's trajectory, in the sagittal sections of each mini-implant. Before the measurements, the CBCT files were renamed with a coded identification number, in the BlueSky software (Blueskybio.com, Blue Sky Bio®), to avoid bias. The anatomical features of the maxillary region were assessed through CBCT scans using the BlueSky software (Blueskybio.com, Blue Sky Bio®), a reference software for guided surgery protocols.[7] The orientation of the head position was determined based on a previous methodology.[8]

STATISTICAL ANALYSIS

Regarding the reproducibility and repeatability of the measurements obtained from the CBCT scan measurements (bone thickness at the mini-implant installation site), they were repeated in 20% of the total sample four weeks after the first measurement. The method error was then calculated using the concordance correlation coefficient.[9] A significance level of 5% was adopted.

The Shapiro-Wilk normality test was applied to all data. The variables showed a normal distribution and homogeneity (data and histograms were considered); therefore, the mean and standard deviation were used to describe the data.

The sex distribution of the patients was described using absolute and relative frequencies, and the difference between the sexes was verified using the chi-squared tests.

Nominal variables were described using absolute and relative frequencies, and the difference in their distributions between sexes was verified using Mann-Whitney tests. For the numerical variables, the difference between the sexes was verified using analysis of variance with Bonferroni correction.[9] For the bone thickness measurements taken from the same patient on both sides, the average between the right and left sides was considered.

Analyses were conducted using IBM-SPSS for Windows software version 20.0, tabulated using Microsoft-Excel software version 2309, and the tests were performed at a 5% significance level.

RESULTS

METHOD ERROR

The average correlation coefficient obtained for the tomographic measurement variables evaluated in this study was 0.918 ± 0.17.

INITIAL DATA, PREVALENCE AND SEX COMPARISON

Only age showed a non-normal distribution (Table 1). No statistically significant differences were observed in the distribution of the patients evaluated, in terms of sex and age. The median age of the 135 patients was 27.3 years (10.8–59.5), comprising 74 men and 61 women with a median age of 27.1 (12.1–59.5) and 24.3 (10.8–55.3) years, respectively (Table 1).

GENERAL ASPECTS OF MARPE

No statistically significant differences between the sexes were observed in terms of the teeth used to support the device. In 90% of cases, maxillary first molars were used as supports, and second molars were used, with teeth #17 and #26 or teeth #26 and #17, to a lesser extent. Them second premolars were used in only one case.

The most commonly used expander screw was 13 mm in diameter (64.1% of cases), with no significant differences between the sexes.

Planning with 4 and 6 mini-implants had a homogeneous distribution, with 73 and 62 cases with 4 and 6 mini-implants, respectively, without significant differences between the sexes.

The reasons for choosing skeletal rings varied greatly, with 33.3% (Table 1) ensuring that the mini-implants were positioned anterior to the transverse palatine suture. Due to the reduced bone thickness in the posterior region (31.9%) and Class III cases (28.9%) (Table 1), these patients received skeletal rings, with no significant differences between the sexes.

The skeletal rings were most frequently located in the alveolar process (41.5%), followed by the paramedian region (37.8%). In 28 patients in whom a skeletal ring was planned (20.7%), the location was both paramedian and alveolar (Table 1).

Many skeletal rings were planned between the second premolars and first molars (41.9%). In 36% of cases, the skeletal rings were positioned between the molars, and in a minority of cases (22.1%), they were positioned distal to the second molars.

Table 1: Distribution of sex, age, and general aspects of MARPE.

	Both n (%)	Female n (%)	Male n (%)	P
Sex: n (%)	135 (100)	61 (45.2)	74 (54.8)	0.263
Age – median (min-max)	27.3 (10.8 – 59.5)	24.3 (10.8 – 55.3)	27.1 (12.1 – 59.5)	0.277[1]
GENERAL ASPECTS OF MARPE				
Support teeth for MARPE				0.086
First permanent molars	122 (90)	52 (42.6)	70 (57.4)	
Second permanent molars	6 (4.4)	6 (100)	0	
First right permanent molar, second left permanent molar	3 (2.2)	1 (33.3)	2 (66.7)	
First left molar, second right molar	3(2.2)	2 (66.7)	1 (33.3)	
Second premolars	1 (0.7)	0	1 (100)	
Expander screw size				0.184
11mm	48 (35.6)	18 (37.5)	30 (62.5)	
13mm	87 (64.1)	43 (49.4)	44 (50.6)	
Quantity of mini-implants				0.733
4	73 (54.1)	32 (43.8)	41(56.2)	
6	62 (45.9)	29 (46.8)	33 (53.2)	
MARPE WITH SKELETAL RINGS				
Reason for using skeletal ring				0.606
Ensure anterior positioning from the transverse palatine suture	45 (33.3)	23 (51.1)	22 (48.9)	
Reduced bone thickness in the posterior region	43 (31.9)	17 (39.5)	26 (60.5)	
Generalized reduced bone thickness	6 (4.4)	2 (33.3)	4 (66.7)	
Class III patient	39 (28.9)	18 (46.2)	21 (53.8)	
Thick mucosa	1 (0.7)	1 (100)	0	
Agenesia	1 (0.7)	0	1 (100)	
Skeletal rings location				0.783
Alveolar process	56 (41.5)	23 (41.1)	33 (58.9)	
Paramedian region	51 (37.8)	27 (52.9)	24 (47.1)	
Both	28 (20.7)	11 (39.3)	17 (60.7)	
Exact position of the skeletal rings				0.985
Between premolars	0	0	0	
Between second premolars and first permanent molars	36 (41.9)	20 (55.6)	16 (44.4)	
Between molars	31 (36)	9 (29)	22 (71)	
Distal from second molars	19 (22.1)	7 (36.8)	12 (63.2)	

[1] Mann-Whitney test.

*p<0.05; **p<0.01; ***p<0.001; ****p<0.0001.

BONE THICKNESS AND CORTICAL POSITIONING AT THE MINI-IMPLANT SITE

A greater thickness of bone was observed when comparing men (10.1 ± 2.1 mm) with women (9.4 ± 2.1 mm) (Tab. 2), for the cases of mini-implants with skeletal rings in the paramedian region; without statistically significant difference. Although the prevalence of bicorticality was higher in men (p=0.003) (Table 2).

Mini-implants with a skeletal ring in the alveolar region presented bone thickness of 8.6 ± 2.9 mm in both sexes. The frequencies of positioning were 20% monocortical, 68.2% bicortical, and 11.8% tricortical, with no differences between the sexes (Table 2).

The anterior mini-implants (conventional MARPE) showed greater insertion in bone in men (5.9 ± 2mm), with a statistically significant difference (p= 0.025). There was no difference between the sexes in terms of cortical positioning, with most cases being bicortical (97.1%) (Table 2).

All posterior mini-implants were bicortical, and the sex distribution was homogeneous. The thickness of the bone in the mini-implant region was also homogeneous (3.31 ± 1.2 mm) (Table 2).

The extra mini-implants (anterior region) were inserted with greater bone thickness in men (11.1 ± 2.3 mm) compared to women (9.9 ± 1.8 mm), with a statistically significant difference (p=0.041) (Tab. 2). Female patients had a significantly higher frequency of bicortical positioning than that in men (p=0.001).

Table 2: Distribution of positioning in relation to the cortical bone. Bone thickness within the mini-implant insertion area (comparison between the sex - ANOVA test with Bonferroni correction).

	Both	Female	Male	SE	P
MINI-IMPLANTS ASSOCIATED WITH THE SKELETAL RING					
Bone thickness - Paramedian region (mm)	9.8 ± 2.1	9.4 ± 2.1	10.1 ± 2.1	0.2	0.091
Positioning of the mini-implants - Paramedian region: n(%)					0.003**
Monocortical	28 (18.2)	15 (53.6)	13 (46.4)		
Bicortical	126 (81.8)	57 (45.2)	69 (54.8)		
Bone thickness - Alveolar Process region (mm)	8.6 ± 2.9	8.1 ± 2.7	8.9 ± 2.9	0.2	0.093
Positioning of the mini-implants - Alveolar Process: n(%)					0.628
Monocortical	34 (20)	9 (26.4)	25 (73.6)		
Bicortical	116 (68.2)	47 (40.5)	69 (59.5)		
Tricortical	20 (11.8)	14 (70)	6 (30)		
Bone thickness extra skeletal ring - Anterior region (mm)	9.3 ± 0.7	8.7 ± 0.3	9.5 ± 0.7	0.2	0.211
Positioning of extra skeletal ring - Anterior region: n(%)					0.564
Monocortical	3 (37.5)	1 (33.3)	2 (66.7)		
Bicortical	5 (62.5)	1 (20)	4 (80)		
MIN-IMPLANTS WITHOUT SKELETAL RINGS					
Anterior miniImplant bone thickness (mm)	5.6 ± 2.1	5.1 ± 2.2	5.9 ± 2	0.2	0.025*
Positioning the anterior mini-implant: n(%)					0.412
Monocortical	3 (2.8)	2 (66.7)	1 (33.3)		
Bicortical	103 (97.1)	44 (42.7)	59 (57.3)		
Posterior mini-implant bone thickness (mm)	3.31 ± 1.2	3.3 ± 1.1	3.3 ± 1.4	0.1	0.912
Positioning the posterior mini-implant: n(%)					1.000
Monocortical	0	0	0		
Bicortical	172 (100)	88 (51.2)	84 (48.8)		
Extra mini-implant bone thickness - anterior region (mm)	10.6 ± 2.2	9.9 ± 1.8	11.1 ± 2.3	0.3	0.041*
Positioning the extra mini-implant - Anterior region: n(%)					0.001**
Monocortical	26 (46.4)	4 (15.3)	22 (84.6)		
Bicortical	30 (53.6)	18 (60)	12 (40)		

*p<0.05; ** p <0.01; ***p<0.001; ****p<0.0001.

DISCUSSION

Understanding the possibilities of appliance design for the MARPE technique is important because we can observe numerous anatomical variations during digital planning.[3] Therefore, this study aimed to present and discuss the factors that influenced the design of these appliances.

The size of the expander screw used can vary depending on the design possibilities. From the data obtained in the present study, patients were more likely to use a 13-mm expander screw (64.1%; Table 1), suggesting that most patients required a large amount of maxillary expansion.

About the support teeth, according to the existing literature,[1,10] the bands are made in the first upper molars, as was the case in most patients in this sample (90%) (Table 1). However, 10% of the patients presented mutilation, indicating that it was necessary to alter the appliance's supporting teeth and modify its design.

The conventional MARPE appliance has four parasutural mini-implants, and is positioned vertically and centered on the maxilla (Fig 3). According to Lee et al.,[10] teeth should be used as a reference for positioning the appliance, that is, the MARPE should be positioned in the first premolars and first molars.

This design does not consider the most anterior region of the maxilla, which has pronounced bone thickness;[11,12] therefore, skeletal support may be inadequate (minor bone thickness). In the present study, the region of the anterior mini-implants had greater bone thickness in men (5.9 ± 2 mm, Table 2), with a statistically significant difference (p=0.025). The mini-implants were positioned bicortically in both sexes, which is critical for the MARPE technique's success.[13,14] An important feature of conventional MARPE is that the positioning of the anterior mini-implants must be performed with caution, as its design has a fixed distance between the anterior and posterior mini-implants, which can lead to a collision with the nasopalatine duct or the transverse palatine suture.[3]

Bone thickness in the posterior paramedian region had a mean thickness of 3.31 ± 1.2 mm, which required additional rings to increase skeletal anchorage (six mini-implants), as the MARPE with four mini-implants would not provide adequate anchorage. In other words, the bone thickness in the posterior paramedian region influences the use of four or six mini-implants. In 100% of the cases, additional rings were placed with bicortical positioning in male and female patients. However, this does not imply the success of the technique because the thickness could be reduced in this region, as

discussed earlier. This occurred in 31.9% of patients (Table 2), which calls for attention, as there may be side effects on the supporting teeth, bone loss around the mini-implants, and failure due to this loss.[15]

The design with additional mini-implants in the anterior maxillary region (Fig 6) is indicated to increase anchorage and chances of success of cases, by ensuring two more skeletal anchorage areas in the anterior region, in a region with adequate bone volume in the anterior nasal spine area.[4] In this region, there is a greater bone thickness in male patients (approximately 0.4 mm) (Table 2). Consequently, female patients showed a statistically significant difference in bicortical positioning in this region, due to the reduced bone volume. In 49.5% of the evaluated cases, the appliances were modified with additional mini-implants due to reduced or increased bone thickness (torus palatinus).[3]

When comparing the bone thickness of the mini-implants between the conventional MARPE (5.6 ± 2.1 mm) and using additional rings (10.6 ± 2.2 mm, Table 2), the anterior paramedian region towards the anterior nasal spine had a greater bone volume. Thus, planning with four and six mini-implants had a homogeneous distribution, which might indicate that 50% of the patients had altered bone thickness, and MARPE with six mini-implants was indicated.

A design with skeletal rings in the anterior region (37.8% of cases; Table 2) (Fig 4) was used in cases with reduced anteroposterior size of the maxilla, ensuring that the mini-implants were positioned anterior to the transverse palatine suture (33%) (Table 1). In cases of increased volume of the nasopalatine foramen, mini-implants can be inserted angled, to avoid colliding with the structure. At this site, male patients had greater bone thickness, as observed with additional mini-implants. There was also a higher frequency of bicortical positioning in male patients. The great advantage of skeletal rings is in combined mechanics, such as reverse traction of the maxilla and expansion, which benefits from the use of the skeletal ring, due to the locking of the mini-implants to the appliance, preventing any dental side effects of mesialization, movement from the expander screw to the anterior, and inflammation of the mucosa in this region.

Skeletal rings can also be used in the alveolar process (Fig. 5), where these mini-implants were inserted in 41.5% of cases, with a bone thickness of 8.6 ± 2.9 mm, 20% of which were monocortical, 68.2% bicortical and 11.8% tricortical. The site of placement of these mini-implants should be selected carefully, assessing the bone volume, mucosal thickness, space between tooth roots, mini-implant insertion axis, and location of the greater palatine artery.

In the designs with skeletal rings in the alveolar process, the majority were positioned between the second premolars and first molars (41.9%), followed by the position between molars (36%). In a minority of cases (22.1%), the skeletal rings were positioned distal to the second molars, due to the lack of an insertion axis of the device or bone volume, with only 11.8% of mini-implants being tricortical, 20% of cases were monocortical, and the highest frequency was bicortical positioning (68.2%). The bicortical positioning of mini-implants allows for a broader distribution of expansion forces, preventing the concentration of stress areas around the mini-implants, and resulting in improved skeletal changes.[13,14] This variation in prevalence between bicortical and monocortical positioning is attributed to factors such as root placement, bone volume, and the range of mini-implant sizes available in the market.[12]

In complex cases, the anterior and alveolar process skeletal rings can be combined (Fig 7). The combination of skeletal rings in the alveolar process and additional anterior rings occurred in 20.7% of the cases planned with a skeletal ring. This suggests a high frequency of more complex cases in this study, where reduced posterior bone thickness, with a reduced anteroposterior limit was noted, not allowing the mini-implants to be placed before the transverse palatine suture, with the need for angulation of the posterior mini-implants or even with reduced stability for maxillary protraction.

Although the conventional MARPE appliance is more likely to be bicortical, it is not installed in a region with good bone volume, due to the anteroposterior limit. Specifically, the mini-implants can touch the nasopalatine nerve and duct, as well as the transverse palatine suture, if not planned three-dimensionally. Additional mini-implants are an excellent tool for cases of varying bone volume and an enlarged nasopalatine duct; however, in cases of maxillary protraction, associated distalization, or reduced parasutural bone thickness, it is ideal to use skeletal rings (skeletal ring stabilizes the appliance, preventing collision with soft tissue or loss of anchorage).

In this study, we illustrated that the design of the appliance can vary according to the amount of expansion, supporting teeth, the thickness of soft and hard tissues, anatomical variations such as palatal torus, and increased diameter of the nasopalatine duct. Thus, the MARPE appliance must be customized for each patient, and guided digital planning must be performed for safe and predictable treatment.

CONCLUSIONS

- Prefabricated appliances have limitations in providing the amount of bone thickness in the anterior region (anteroposterior distance already defined), compared to the appliance with additional rings.
- Additional rings, whether with or without internal threads, make it possible to be inserted in more bone, due to the possibility of customization. Additionally, they prevent collisions with important structures.
- Mini-implants int the alveolar process region seems to be a satisfactory option to patients with reduced bone thickness in the paramedian posterior region.
- Male patients had greater bone thickness than female, which may be related to greater difficulty in opening the sutures. MARPE appliances must be customized for each patient, due to several potential anatomical variations. Guided digital planning should be conducted to ensure safety and predictability.

AUTHORS' CONTRIBUTIONS

Cristiane Barros André (CBN)

Bruno de P. M. Pasqua (BPMP)

Gustavo de Andrade Jacquier (GAJ)

Fábio Dupart Nascimento (FDN)

Conception or design of the study:

CBN, BPMP

Data acquisition, analysis or interpretation:

CBN, BPMP, GAJ, FDN

Writing the article:

CBN, BPMP

Critical revision of the article:

CBN, BPMP, GAJ, FDN

Final approval of the article:

CBN, BPMP, GAJ, FDN

Fundraising:

CBN

Overall responsibility:

CBN, FDN

» The authors report no commercial, proprietary or financial interest in the products or companies described in this article.

REFERENCES

1. Brunetto DP, Sant'Anna EF, Machado AW, Moon W. Non-surgical treatment of transverse deficiency in adults using Microimplant-assisted Rapid Palatal Expansion (MARPE). Dental Press J Orthod. 2017 Feb;22(1):110-25.

2. André CB. MARPE Guide: da consolidação à evolução da técnica. Clín Ortod. 2020;19(5):48-56.

3. André CB, Pasqua BPM, Rino Neto J, Nascimento FD. Surgical digitally guided planning for the Mini-Screw Assisted Rapid Palatal Expansion (MARPE) and suture perforation: MARPE guide. 2021 [Access 8 May 2024]. Available from: https://www.intechopen.com/chapters/78828.

4. Cury SEN, Mondelli AL, André CB, Iared W, Guerra JGP, Rovira J, et al. Protocolo diferencial para a técnica MARPE em pacientes com variação no volume ósseo do palato. Rev Clín Ortodon Dental Press 2019;18(4):116-29.

5. André CB. Skeletal ring: a new resource for complex cases. Clin Orthod. 2023;22(2):60-71.

6. Wilmes B, Ludwig B, Vasudavan S, Nienkemper M, Drescher D. The T-Zone: median vs. paramedian insertion of palatal mini-implants. J Clin Orthod. 2016 Sep;50(9):543-51.

7. Cretu C, Agop-Forna D, Bardi D, Cristea I, Dascălu C, Petruţa S, et al. Accuracy of computer-aided implant surgery. Rom J Oral Rehabil. 2023;15:406-15.

8. Pasqua BPM, André CB, Paiva JB, Tarraf NE, Wilmes B, Rino-Neto J. Dentoskeletal changes due to rapid maxillary expansion in growing patients with tooth-borne and tooth-bone-borne expanders: a randomized clinical trial. Orthod Craniofac Res. 2022 Nov;25(4):476-84.

9. Kirkwood BR, Sterne JAC. Essential medical statistics. 2nd ed. Malden: Blackwell Science; 2003.

10. Lee KJ, Park YC, Park JY, Hwang WS. Mini-implants-assisted nonsurgical palatal expansion before orthognathic surgery for a patient with severe mandibular prognathism. Am J Orthod Dentofacial Orthop. 2010 Jun;137(6):830-9.

11. Becker K, Unland J, Wilmes B, Tarraf NE, Drescher D. Is there an ideal insertion angle and position for orthodontic mini-implants in the anterior palate? A CBCT study in humans. Am J Orthod Dentofacial Orthop 2019 Sep;156(3):345-54.

12. Alves ACM, Carvalho NO, Cunha ÂCPP, Rabelo SGF, Pereira HSG. Do the miniscrews of the prefabricated systems for the "appliance first" protocol of miniscrew-assisted rapid palatal expansion have lengths that meet the palatal thickness of patients? Am J Orthod Dentofacial Orthop. 2023 Jun;163(6):e152-61.

13. Lee DW, Park JH, Moon W, Seo HY, Chae JM. Effects of bicortical anchorage on pterygopalatine suture opening with microimplant-assisted maxillary skeletal expansion. Am J Orthod Dentofacial Orthop. 2021 Apr;159(4):502-11.

14. Li N, Sun W, Li Q, Dong W, Martin D, Guo J. Skeletal effects of monocortical and bicortical mini-implant anchorage on maxillary expansion using cone-beam computed tomography in young adults. Am J Orthod Dentofacial Orthop. 2020 May;157(5):651-61.

15. Meirelles CM, Ferreira RM, Suzuki H, Oliveira CB, Jesus AS, Garcez AS, et al. Analysis of factors associated with the success of microimplant-assisted rapid palatal expansion. Am J Orthod Dentofacial Orthop. 2023 Jul;164(1):67-77.

4.3.4 Guided corticopuncture associated with microimplant-assisted rapid palatal expansion (MARPE): planning variables

Abstract

Objectives: This study analyzed the planning of guided corticopuncture (suture weakening associated with microimplant-assisted rapid palatal expansion) in 171 patients to understand the variables that define and limit this type of treatment.

Materials and Methods: 171 cone beam computed tomography (CBCT) scans of patients of both sexes with a mean age of 33.4 ± 10.4 years were evaluated using the Blue Sky Bio® software. The variables assessed were the number of virtually planned perforations (midpalatal suture, transpalatal, and intermaxillary), distance between them, average angulation, and bone and soft tissue thicknesses. The nominal variables were described using absolute and relative frequencies, and the difference between the distributions according to sex was verified using Mann–Whitney test (5% significance level).

Results: A mean of 5.68 ± 1.31 perforations were observed in the midpalatal suture, with distance of 2.03 ± 0.5 mm, and angulation was 90.75 ± 5.32° in the sagittal section, and 90.17 ± 2.19° in the coronal section. The thickness of the mucosa was greater in males (2.17 ± 0.74 mm) than in females (1.85 ± 0.55 mm). In the intermaxillary suture, the number of perforations was 2.78 ± 0.42, the distance between them was 1.65 ± 0.18 mm, the angulations averaged 146.37 ± 9.4°.

Conclusion: The angulation of the perforations was more pronounced in the intermaxillary suture. There was no difference between the sexes in the planning of the quantity, distance, and inclination of the cortico-punctures. Male patients had a greater amount of soft tissue in the perforations.

Keywords: Maxillary expansion; orthodontic anchorage technique; cone-beam computed tomography.

Introduction

The microimplant-assisted rapid palatal expansion (MARPE) technique involves rapid maxillary expansion (RME) in adult patients using a device supported by mini-implants, allowing orthopedic expansion with few adverse effects.[1,2] This procedure is

well accepted by patients because, in addition to its lower cost, it is less invasive than surgically assisted rapid maxillary expansion.

Even with the virtual planning associated with MARPE,[3,4] there are complex cases of variation in maxillary thickness where the resistance to opening the sutures is greater, as well as factors such as advanced age, advanced maturation of the midpalatal suture, anatomical variations such as the presence of a palatine torus, and a maxillary size greater than the average for the population. Suzuki *et al*.[5] proposed creating corticopunctures in the region of the midpalatal suture prior to RME to reduce resistance during expansion by weakening the midpalatal suture.

Although it has shown positive results,[6-8] it is not a precise procedure, since the anatomical reference for drilling is the palatine raphe (soft tissue), which does not always coincide with the midpalatal suture itself. This suture can also present variations like sinuosity. In addition, drills are used empirically and may not reach the cortical nasal floor or even perforate the nasal septum (in the case of patients with thin palatine bones). This can cause pain for the patient and oral–nasal communication, which can result in sinusitis, or in more severe cases, it can progress to bone necrosis or osteomyelitis.[4] The direct technique also fails when the perforation is too close to the mini-implant installation area, which can create a weakening zone in areas that require bone support.[8]

To ensure safety and efficacy, André *et al*.4 developed virtually guided drilling. By superimposing the intraoral digital scan file and cone beam computed tomography (CBCT) (DICOM), it is possible to choose the correct location precisely and safely for perforation of the sutures. After planning the perforations, a guide is created that reproduces the virtual plan and has a stop, to limit the insertion of the drill and carry out these perforations.4 This planning was carried out together with MARPE in virtual form to avoid perforation close to the mini-implants·[4] With the advent of the guided technique, suture perforations have become a common procedure and are very important in the posterior region, as these regions present resistance during RME,[9,10] as well as in the anterior region (intermaxillary suture).

Therefore, this study aimed to analyze the planning of guided perforations in 171 cases to understand the variables that can define planning, and the factors that can potentially limit it. Up to the present, there is no clear guidance in the literature on the indications and planning of this new procedure.

Methods

Study design

This cross-sectional study analyzed variations in 171 guided corticopuncture plans from patients aged 17–54 years from both sexes.

Ethical approval

This study was approved by the Ethics Committee of our University (CAAE: 55356821.1.0000.5497., approval number: 5.360.812). Informed consent was not required as all the CBCT images were obtained in the past and used for planning rapid maxillary expansion associated with mini-implants (MARPE). All data were anonymized prior to the investigation.

Inclusion and exclusion criteria

The inclusion criteria were: CBCT scans carried out between 2022 and 2023; patients aged 17–54 years, of both sexes who had a transverse maxillary deficiency and the need for maxillary expansion using mini-implants; indication of suture weakening, due to advanced age; skeletal maturation of the suture at an advanced stage; palatal torus; and variation in bone and soft tissue thickness. The exclusion criteria consisted of patients with nasopalatine clefts, craniofacial syndromes or malformations.

Measurements

The CBCT was previously obtained using the iCAT (Imaging Sciences International, Hatfield, Pennsylvania) with the following settings: 120 kVp, 18 mA; exposure time, 8.9 s; voxel size, 0.2 mm; and a field of view (FOV) of 160 × 60 mm.

Only CBCT scans of the maxillary region were used and the head position was standardized in the Blue Sky Bio® software version 4.7.55 (Blueskybio.com, Blue Sky Bio ®) following a previous methodology.[11] The variables evaluated were the number of perforations planned virtually in the sutures (midpalatal, transpalatal, and intermaxillary sutures; Figure 1), distance between the perforations, thickness of the drills used, average angulation of the perforations in relation to the palatal plane in the sagittal section (Figure 2), bone thickness in the sagittal section of the midpalatal and

transpalatal sutures (Figure 3), and soft-tissue thickness in the sagittal section of the midpalatal and transpalatal sutures.

Figure 1 - Perforations of the median palatine suture (A) and intermaxillary suture (B).

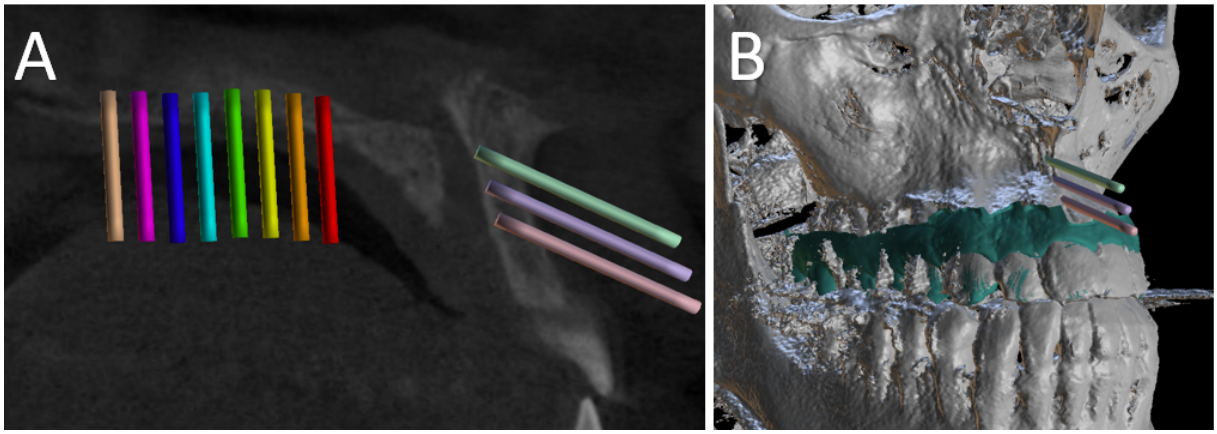

Fonte: Próprio autor

Figure 2 - Angulation of the perforation in relation to the palatal plane.

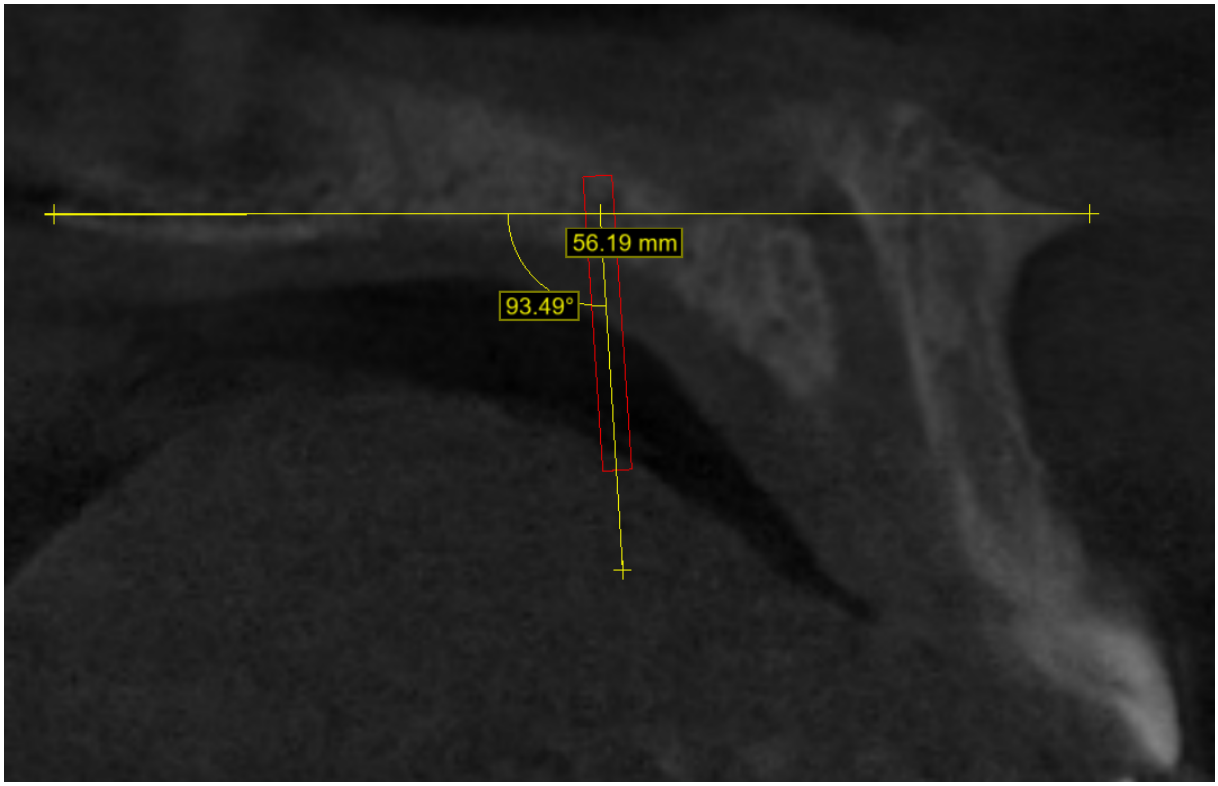

Fonte: Próprio autor

Figure 3 - (a) Bone and soft tissue thickness of the median palatine suture perforation. (b) Bone and soft tissue thickness of the transpalatal suture perforation.

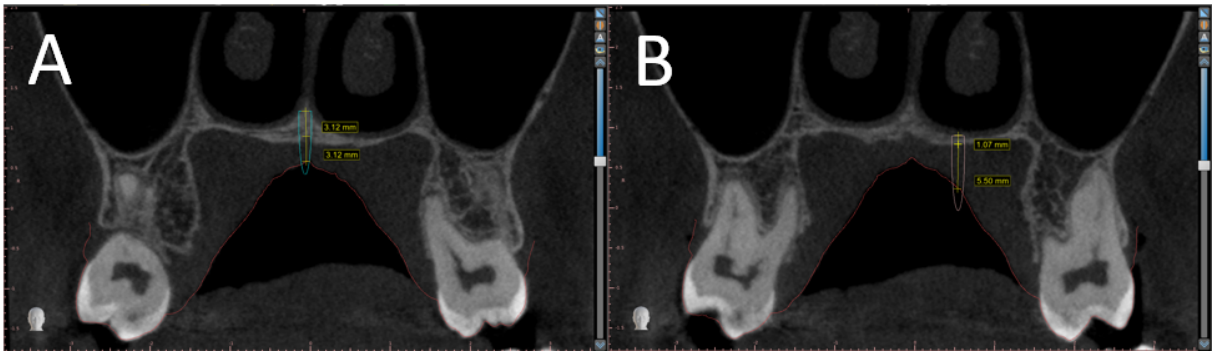

Fonte: Próprio autor

Statistical analysis

Regarding the reproducibility and repeatability of the measurements obtained from the CBCT scans, the measurements were repeated on 20% of the total sample 4 weeks after the first measurement. The method error was calculated using the concordance correlation coefficient. The significance level was set at 5%.

The Shapiro–Wilk normality test was applied to all data. The variables showed a normal distribution and homogeneity (data and histograms were considered); therefore, the mean and standard deviation were used to describe the data.

Nominal variables were described using absolute and relative frequencies, and the difference between sexes was verified using chi-squared tests.[12]

For numerical variables, differences between the sexes were verified using analysis of variance (ANOVA) with Bonferroni correction.[12]

The analyses were performed using IBM SPSS software (version 20.0 IBM, Armonk, NY, USA), tabulated using Microsoft Excel software version 2309, and the tests were conducted at a 5% significance level.

Results

Method error

The average correlation coefficient obtained for the 20 variables evaluated in this study was 0.937 ± 0.13.

Baseline data, prevalence, and comparison between sexes

The mean age of the patients was 33.4 ± 10.4 years, with no statistically significant difference in terms of sex (Table 1). The sex distribution was homogeneous (52% of total sample comprised female patients and 48% male patients). The 1.6 mm

drill thickness was used most frequently (83.6% patients), and there was no difference between the drill thicknesses used in relation to sex (Table 1).

Perforations of the midpalatal suture were observed in both sexes, with a mean of 5.68 ± 1.31. The average distance between the perforations was 2.03 ± 0.5 mm, and the angulation of these perforations was 90.75 ± 5.32° in the sagittal section and 90.17 ± 2.19° in the coronal section (Table 1). An average thickness of 5.18 ± 1.65 mm was observed in the region of the perforations, with no difference between the sexes. The thickness of the mucosa was greater in males (2.17 ± 0.74 mm) compared to females (1.85 ± 0.55 mm), with a statistically significant difference (p=0.001, Table 1).

In the intermaxillary suture (anterior region), the average number of perforations was 2.78 ± 0.42, considering both sexes. The average distance between the perforations was 1.65 ± 0.18 mm, and the angulations averaged 146.37 ± 9.4° (Figure 1).

Considering the transpalatal sutures, the average number of perforations was 2.31 ± 0.73. Regarding the thickness of the transpalatal suture region, there were statistically significant differences between sexes. Bone thickness was approximately 0.5 mm greater in males, with a statistically significant difference (p=0.000). Soft tissue thickness was on average 1.1 mm greater in males, with a statistically significant difference (p=0.039).

Table 1 - Characterization of the sample and comparison of the variables between sexes (ANOVA test or Mann-Whitney).

Parameter	N	Both sexes	Female		Male		SE	P
			N	Mean ± SD	N	Mean ± SD		
Age (years)(mean ± SD)	171	33.4 ± 10.4	89	33.15 ± 10	82	33.6 ± 10.85	0.79	0.769
Sex (%)	171(100)		89 (52)		82(48)			0.646 □
Corticopuncture drill (%)								0.289ǂ
1.6mm	143 (83.6)		77(53.8)		66 (46.2)			
2mm	28 (16.4)		12(42.8)		16 (57.12)			
Total	171 (100)		89(52.1)		82(47.9)			
MIDPALATAL SUTURE								
Number of perforations (mean ± SD)	171	5.68 ± 1.31	89	5.77 ± 1.27	82	5.85 ± 1.35	0.1	0.346
Perforations distance (mm)(mean ± SD)	171	2.03 ± 0.5	89	2.02 ± 0.39	82	2.03 ± 0.51	0.03	0.867
Angulation of perforations – sagittal slice (°)(mean ± SD)	171	90.75 ± 5.32	89	91.19 ± 5.36	82	90.2 ± 5.27	0.4	0.262
Angulation of perforations – coronal slice: (°)(mean ± SD)	171	90.17 ± 2.19	89	90.1 ± 2.42	82	90.24 ± 1.92	0.16	0.679
Bone thickness – sagittal slice (mm)(mean ± SD)	171	5.18 ± 1.65	89	4.98 ± 1.6 0.823	82	5.4 ± 1.66	0.12	0.101
Soft tissue thickness – sagittal slice (mm)(mean ± SD)	171	2 ± 0.67	89	1.85 ± 0.55	82	2.17 ± 0.74	0.05	0.001^^
INTERMAXILLARY SUTURE								
Number of perforations (mean ± SD)	14	2.78 ±0.42	7	2.71 ± 0.48	7	2.85 ± 0.37	0.11	0.552
Perforations distance (mm)(mean ± SD)	14	1.65 ± 0.18	7	1.71 ± 0.22	7	1.60 ± 0.12	0.18	0.305
Angulation of perforations – sagittal slice (°)(mean ± SD)	14	146.37 ± 9.4	7	146.58 ± 8.73	7	146.17 ± 10.7	2.51	0.939
Bone thickness – sagittal slice (mm)(mean ± SD)	14	8.92 ± 1.72	7	8.1 ± 0.54	7	9.62 ± 2.11	0.47	0.116
TRANSPALATAL SUTURE								
Perforations distance (mm)(mean ± SD)	66	2.31 ± 0.73	37	2.27 ± 0.69	29	2.37 ± 0.77	0.08	0.549
Bone thickness – sagittal slice (mm)(mean ± SD)	66	1.97 ± 1,03	37	1.73 ± 0.59	29	2.27 ± 1,36	0.12	0.039^
Soft tissue thickness – sagittal slice (mm)(mean ± SD)	66	3.7 ± 1.29	37	3.2 ± 0.82	29	4.36 ± 1.5	0.16	0.000^^^

SD: standard deviation
SE: standard error
□ *Chi-square test*
ǂ Mann Whitney test
^P<.05; ^^P<.01; ^^^P<.001; ^^^^P<.0001

Fonte: Próprio autor

Discussion

The use of corticopuncture as a complementary procedure to MARPE in adults is now a reality.[6-8] However, because this is a new technique, there is a lack of data regarding the planning of these perforations, such as the number of perforations, angulation, and the distance between them. Therefore, this study aimed to present data from 171 plans, including the average number of perforations, inclination, and distance between them, and the sutures most frequently perforated, to understand the possible factors that may influence this type of planning.

Regarding data obtained for the midpalatal suture, an average of 5.68 ± 1.31 perforations were made, with an average distance of 2.03 ± 0.5 mm and an inclination in relation to the palatal plane of 90.75 ± 5.32°. The number of perforations varied according to maxillary size. For example, the number of perforations was reduced in patients with smaller sagittal maxillae. The angulation of each perforation was carefully determined in digital planning, with the aim of obtaining the correct insertion axis for the contralateral angle in the mouth, because inclinations of > 90° in both the sagittal section in relation to the palatal plane and the coronal section in relation to the nasal floor plane can make insertion in the mouth difficult. In addition, this angulation allowed us to weaken a greater volume of bone compared with a totally vertical insertion (Figure 1).

Few patients experienced perforations in the intermaxillary suture (8.1%), as this was a recent protocol. Although Brunetto *et al*.[9] reported that the posterior region was the site of greatest resistance to maxillary expansion, the anterior region of the maxilla was also resistant; this region has a pronounced bone volume[13,14] and, therefore, causes greater resistance to opening during RME. Therefore, in patients with a greater chance of failure, that is, advanced age and skeletal maturation,[15-18] the corticopucture is recommended. The number of perforations in this region averaged 2.78 ± 0.42, with a distance of 1.65 ± 0.18 mm between them, and an angulation of 146.37 ± 9.4°. The angulation was more pronounced because of the inclination of the anterior region of the maxilla (Figure 1). In this region, the number of perforations is limited because the area is small, due to the superior labial frenum and the lip. Intermaxillary suture perforations should be carefully planned to avoid collisions with

the roots of the central incisors. The trajectory of these perforations follows the same line of thought mentioned above, using an inclined drill to weaken a larger area.

The number of patients in whom drilling was performed in the transpalatal suture region was low (38.6%). This is because it is a site with little bone thickness, and in some patients, there were already bone defects in this region; therefore, drilling was not performed.

The distance between the perforations and their inclinations was not statistically significant between the sexes; however, the distance between the perforations was also directly related to the success of the corticopuncture guide impression, with distances of < 1 mm likely to fail during the impression process.

Some studies have reported that adult male patients, especially those aged > 25 years, have the highest chances of failure.[19, 20] In the present study, a greater soft tissue thickness was observed in the region of the midpalatal and transpalatal sutures (Table 1). It is understood that the greater the amount of soft tissue, the greater the unanchored space (distance between the hard tissue and the appliance), and the greater the chances of these mini-implants tilting due to the tension exerted during activation, which is a factor in the potential failure of the technique.[10] Regarding bone thickness, there were no statistically significant differences in bone thickness in relation to sex, either in the posterior or anterior region (intermaxillary sutures). In contrast, in the transpalatal suture region, there was a more pronounced bone thickness in males, with a statistically significant difference (Table 1). This may be related to the greater resistance to expansion in male patients, which is another factor for failure in these patients. Meirelles *et al*,[7] found that corticopuncture may help suture opening in thin palates, so, those patients take more advantages from corticopuncture before MARPE.

Although male patients had larger maxillae than females, we did not obtain statistically significant data regarding the number of perforations in the midpalatal, transpalatal, and intermaxillary sutures.

An essential factor in corticopuncture planning is the proximity of the perforation to the regions parallel to the mini-implant installation site, which must be preserved regardless of sex. In this way, we prevent weakening in this region because even though it is a band-supported device, there is a considerable amount of tension that

reaches the mini-implant region, which must be circumscribed by an adequate amount of bone.[10]

The perforations must respect the nasopalatine canal, which must be preserved to avoid injury to the nasopalatine nerve and extensive bleeding (Figure 1). Additionally, image acquisition during digital dental planning must cover the entire posterior region of the palate. Due to the smaller image capture area, fewer perforations could be planned along the midpalatal suture (Figure 4). In contrast, the intermaxillary region, is difficult to image capture due to the presence of the labial frenum, so the corticopuncture guide is performed with an internal relief (Figure 5).

Figure 4 - (a) Perforations made with an appropriate digital dental scan. (b) Reduced scanning of the palate, consequently planning fewer perforations.

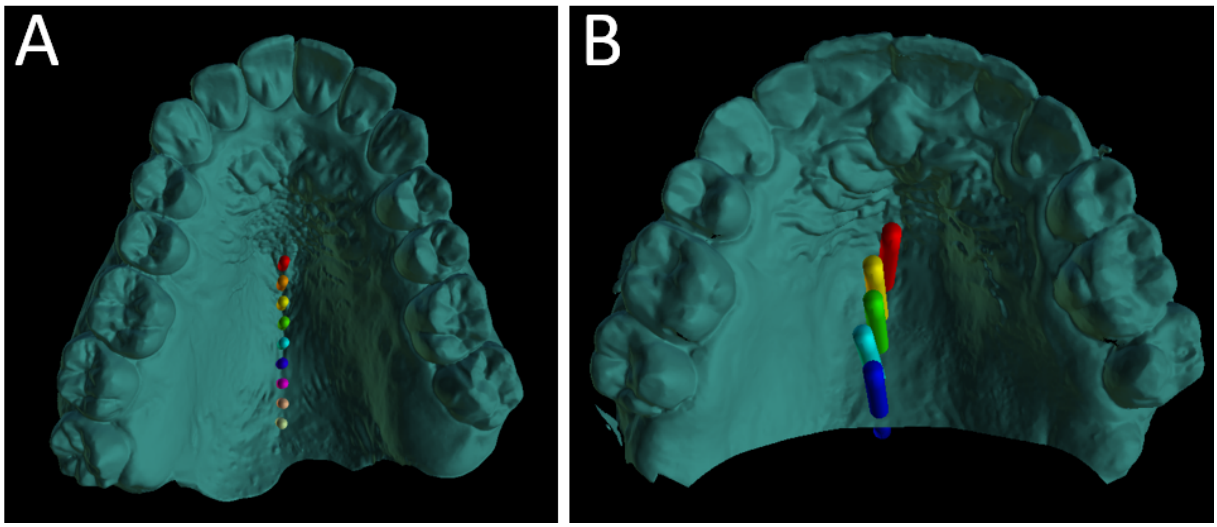

Fonte: Próprio autor

Figure 5 - (a) Virtual planning of the intermaxillary suture perforation guide. (b) Guide for drilling the median palatine and transpalatal sutures.

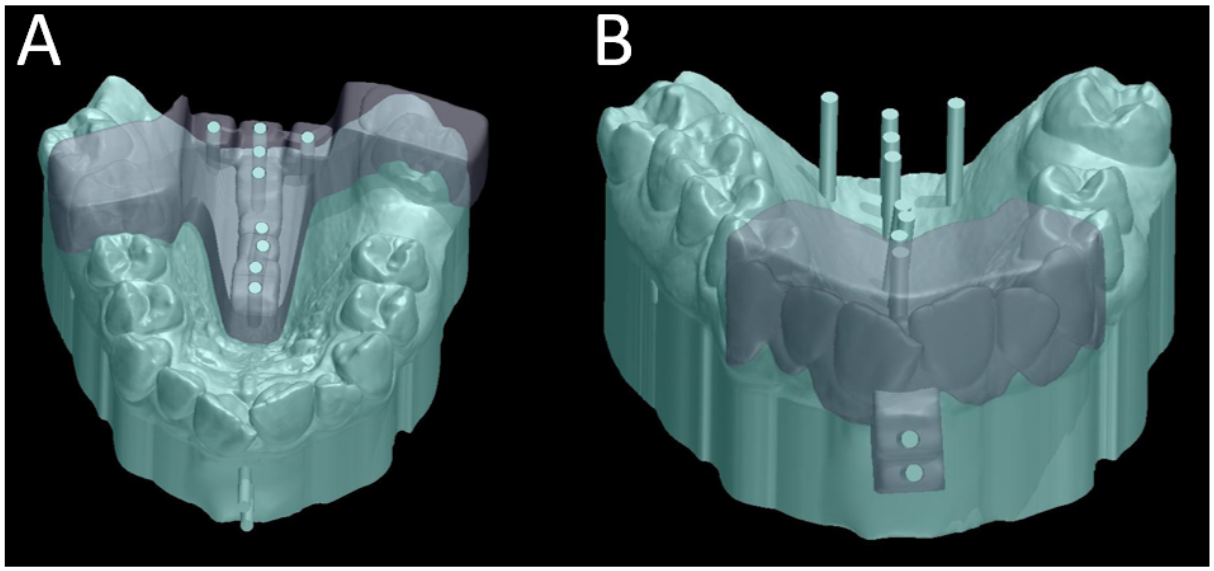

Fonte: Próprio autor

The thickness of the drill used was the personal choice of each orthodontist and had no influence on virtual planning. The thinnest drill was used most often (1.6 mm).

In the present study, we observed that corticopuncture planning for maxillary expansion with MARPE was similar between the sexes. On average, there were five perforations in the midpalatal suture, and three in the intermaxillary and transpalatal sutures. In the midpalatal suture, the angulations were, on average, 90° in relation to the palatal plane and 140° in the intermaxillary suture. This technique can be indicated for patients aged > 25 years as an additional resource to increase the chances of success of the MARPE technique. Given the importance of guided corticopuncture and the data found in this study, further clinical research should be conducted to confirm the benefits of this technique.

Limitations and Generalizability

The primary limitation of this study was its cross-sectional design. The use of retrospective data collection may have introduced bias. To mitigate the selection bias, all tomography scans that met the inclusion criteria were included.

Conclusion

- According to the evaluation of 171 corticopuncture plans from patients with an average age of 33.4 ± 10.4 years, we observed several perforations: 5.68 ± 1.31 in the midpalatal suture, 2.78 ± 0.42 in the intermaxillary suture, and 2.31 ± 0.73 in the transpalatal suture.

- The distance between the perforations was, on average: 2.03 ± 0.5 mm at the midpalatal suture and 1.65 ± 0.18 mm at the intermaxillary suture.

- The angulation of the perforations varied according to the region, with greater angulation in the intermaxillary suture region.

- There was no difference between the sexes in planning the quantity, distance, and inclination of cortical punctures.

- Male patients had a greater amount of soft tissue in the perforated region, which may be related to higher failure rates (greater distance from the mini-implant ring to the hard tissue).

References

1. Celenk-Koca T, Erdinc AE, Hazar S, Harris L, English JD, Akyalcin S. Evaluation of miniscrew-supported rapid maxillary expansion in adolescents: A prospective randomized clinical trial. Angle Orthod. 2018;88:702–9. https://doi.org/10.2319/011518-42.1

2. Choi EA, Lee KJ, Choi SH, Jung HD, Ahn HJ, Deguchi T, *et al*. Skeletal and dentoalveolar effects of miniscrew-assisted rapid palatal expansion based on the length of the miniscrew: A randomized clinical trial. Angle Orthod. 2023;93:390–7. https://doi.org/10.2319/072322-512.1

3. André CB [MARPE guide]: from consolidation to technique evolution. Journal of Clin Orthod: JCO;19; 2020, p. 00–0

4. André CB, Pasqua BPM, Rino-Neto J, Dupart FN. Surgical digitally guided planning for the mini-screw assisted rapid palatal expansion (MARPE) and suture perforation: MARPE guide [Online first]. IntechOpen. https://doi.org/10.5772/intechopen.100226; 2021

5. Suzuki SS, Garcez AS, Reese PO, Suzuki H, Ribeiro MS, Moon W. Effects of corticopuncture (CP) and low-level laser therapy (LLLT) on the rate of tooth movement

and root resorption in rats using micro-CT evaluation. Lasers Med Sci. 2018;33:811–21. https://doi.org/10.1007/s10103-017-2421-5

6. Bud ES, Bică CI, Păcurar M, Vaida P, Vlasa A, Martha K, *et al*. Observational study regarding possible side effects of miniscrew-assisted rapid palatal expander (MARPE) with or without the use of corticopuncture therapy. Biology (Basel). 2021;10:187. https://doi.org/10.3390/biology10030187, PMID: 33802266, PMCID: PMC8001817

7. Meirelles CM, Ferreira RM, Suzuki H, Oliveira CB, Souza de Jesus A, Garcez AS, *et al*. Analysis of factors associated with the success of microimplant-assisted rapid palatal expansion. Am J Orthod Dentofacial Orthop. 2023;164:67–77. https://doi.org/10.1016/j.ajodo.2022.10.029

8. André CB. Guided surgical digital planning for suture cortical perforation: Cortex Guide. J Clin Orthod. 2022;21:74–85

9. Brunetto DP, Sant'Anna EF, Machado AW, Moon W. Non-surgical treatment of transverse deficiency in adults using microimplant-assisted rapid palatal expansion (MARPE). Dental Press J Orthod. 2017;22:110–25. https://doi.org/10.1590/2177-6709.22.1.110-125.sar

10. André CB, Rino-Neto J, Iared W, Pasqua BPM, Nascimento FD. Stress distribution and displacement of three different types of micro-implant assisted rapid maxillary expansion (MARME): A three-dimensional finite element study. Prog Orthod. 2021;22:20. https://doi.org/10.1186/s40510-021-00357-5

11. Pasqua BPM, André CB, Paiva JB, Tarraf NE, Wilmes B, Rino-Neto J. Dentoskeletal changes due to rapid maxillary expansion in growing patients with tooth-borne and tooth-bone-borne expanders: A randomized clinical trial. Orthod Craniofac Res. 2022;25:476–84. https://doi.org/10.1111/ocr.12559

12. Kirkwood BR, Sterne JAC. Essential medical statistics. 2nd ed. MA: Blackwell Publishing Science, p. 502; 2006

13. Wilmes B, Ludwig B, Vasudavan S, Nienkemper M, Drescher D. The T-zone: Median vs. paramedian insertion of palatal mini-implants. J Clin Orthod. 2016;50:543–51

14. Becker K, Unland J, Wilmes B, Tarraf NE, Drescher D. Is there an ideal insertion angle and position for orthodontic mini-implants in the anterior palate? A CBCT study in humans. Am J Orthod Dentofacial Orthop. 2019 Set;156:345–54. https://doi.org/10.1016/j.ajodo.2018.09.019

15. Jesus AS, Oliveira CB, Murata WH, Suzuki SS, Santos-Pinto AD. Would midpalatal suture characteristics help to predict the success rate of miniscrew-assisted rapid palatal expansion? Am J Orthod Dentofacial Orthop. 2021;160:363–73. https://doi.org/10.1016/j.ajodo.2020.04.035. Epub 2021 Jun 24. PMID: 34175160

16. Salmoria I, de Souza EC, Furtado A, Franzini CM, Custodio W. Dentoskeletal changes and their correlations after micro-implant-assisted palatal expansion (MARPE) in adults with advanced midpalatal suture ossification. Clin Oral Investig. 2022;26:3021–31. https://doi.org/10.1007/s00784-021-04284-x. Epub 2021 Nov 13. PMID: 34773143

17. Oliveira CB, Ayub P, Angelieri F, Murata WH, Suzuki SS, Ravelli DB, *et al*. Evaluation of factors related to the success of miniscrew-assisted rapid palatal expansion. Angle Orthod. 2021;91:187–94. https://doi.org/10.2319/051420-436.1, PMID: 33351888, PMCID: PMC8028491

18. Winsauer H, Walter A, Katsaros C, Ploder O. Success and complication rate of miniscrew assisted non-surgical palatal expansion in adults – A consecutive study using a novel force-controlled polycyclic activation protocol. Head Face Med. 2021;17:50. https://doi.org/10.1186/s13005-021-00301-2, PMID: 34895287, PMCID: PMC8665552

19. Jia H, Zhuang L, Zhang N, Bian Y, Li S. Age-dependent effects of transverse maxillary deficiency treated by microimplant-assisted rapid palatal expansion: A prospective cone-beam computed tomography study. Am J Orthod Dentofacial Orthop. 2022;161:557–73. https://doi.org/10.1016/j.ajodo.2020.10.029. Epub 2021 Dec 11. PMID: 34903419

20. Jeon JY, Choi SH, Chung CJ, Lee KJ. The success and effectiveness of miniscrew-assisted rapid palatal expansion are age- and sex-dependent. Clin Oral Investig. 2022;26:2993–3003. https://doi.org/10.1007/s00784-021-04281-0. Epub 2021 Nov 25. PMID: 34821980, PMCID: PMC8898235

5 DISCUSSÃO

No presente trabalho, foram apresentados quatro artigos científicos relacionados ao planejamento de MARPE, com o objetivo de discorrer sobre as variações anatômicas que interferem no planejamento, os benefícios da utilização do planejamento digital, as alterações que estas variações anatômicas e particularidades de cada caso podem influenciar no desenho dos aparelhos, e os dados sobre uma ferramenta adicional para os casos de MARPE: a fragilização da sutura palatina mediana por meio da corticoperfuração guiada.

Das diversas variações anatômicas avaliadas, serão discutidas de forma resumida as mais relevantes e que potencialmente influenciam o planejamento e as chances de sucesso. Foi possível observar que indivíduos adultos podem sofrer reabsorções ósseas na região paramediana e da cavidade nasal, por isso a prevalência de pacientes adultos com espessura óssea reduzida é alta. Para estes casos, fica clara a necessidade de um planejamento minucioso, por exemplo, evitando que os DATs sejam inseridos nestas regiões de falhas ósseas e/ou espessura óssea reduzida. Isto só é possível com o planejamento digital guiado (ANDRÉ *et al*, 2021).

O formato esquelético do palato é outro fator determinante no sucesso da técnica, tanto para os casos de Hyrax híbrido como para os casos MARPE. Foi observado que os pacientes mais jovens normalmente possuem o formato irregular em W, sendo desta forma o planejamento digital para Hyrax Híbrido o mais indicado. Esta anatomia exige que a trajetória do DAT seja calculada e guiada, evitando colisões com estruturas anatômicas importantes e planejando a melhor adaptação dos anéis ao tecido mole, onde o posicionamento deve ser o mais próximo possível do osso. Esta adaptação pode influenciar no sucesso da expansão (ANDRÉ, 2023).

Outra avaliação importante diz respeito a maturação esquelética. A sutura palatina mediana apresentou-se no geral com estágio de maturação avançado, sendo na maioria dos casos o estágio D, o que pode estar associado a uma maior resistência à abertura da sutura palatina mediana (ANGELIERI *et al*, 2016). Porém, as evidências científicas mostram que a variável idade tem uma influência maior sobre as taxas de sucesso do MARPE do que a maturação esquelética, ou seja, quanto maior a idade,

mais avançado é o estágio de maturação e consequentemente maior é a resistência (JANG *et al*, 2016; LUZ *et al*, 2022; NIE *et al*., 2023).

Dentre outros achados importantes, destaca-se a alta prevalência de pacientes com aumento do tamanho do forame nasopalatino, o que justifica o planejamento e confecção de aparelhos totalmente customizados, a fim de não colidir com essa região anatômica. É importante citar que nestes casos os aparelhos industrializados são limitados, por apresentarem uma distância fixa entre os DATs anteriores e posteriores. Isto resulta em contraindicação ao tratamento de expansão com MARPE em grande parte da população, por possuir um canal nasopalatino aumentado. A presença de tórus palatino foi de 23% do total dos casos, o que serve de alerta sobre o aumento de ancoragem e a possibilidade de uma maior resistência à abertura da sutura palatina mediana, sendo indicado a fragilização guiada (ANDRÉ *et al*, 2021; MEIRELLES *et al*, 2023).

No geral, foi possível compreender a importância destes achados e que se trata de um banco de dados inédito na literatura sobre a prevalência de variáveis específicas para a técnica MARPE. Desta forma, entende-se que DATs com inclinações diferentes que evitam a colisão com estruturas importantes, podem ser favoráveis para possibilitar a técnica MARPE em vários casos (ANDRÉ *et al*, 2021). Esta angulação customizada e diferentes tamanhos dos DATs, pode ser algo frequente tendo em vista os resultados encontrados neste estudo.

Visto isso, fica claro que estes tipos de tratamento são inviáveis sem a realização da tomografia e escaneamento intraoral, ou mesmo os planejamentos realizados apenas com referência de medidas bidimensionais na tomografia. Isto impede a customização baseada nas variações anatômicas descritas acima, e ainda não preveem a trajetória dos DATs. Desta forma, além de ser um risco à saúde do paciente, a escolha do tamanho dos DATs poder ser muito subjetiva e susceptível a erros. A utilização do planejamento digital guiado, também chamado de MARPE *guide*, já apresentou resultados interessantes na literatura (ANDRÉ, 2019; MINERVINO *et al*, em 2019, 2020, CANTARELLA *et al*., 2020; ANDRÉ, 2020; LO GIUDICE *et al*, 2020, ANDRÉ *et al*, 2021). Ou seja, a partir da sobreposição da tomografia com o escaneamento, é possível planejar não somente o posicionamento do torno expansor, mas também planejar a trajetória completa dos DATs. Este

planejamento é realizado com o auxílio da ferramenta 3D, mas, impreterivelmente, deve ser avaliado nos três cortes da tomografia (axial, sagital e coronal).

Dentre as vantagens da instalação guiada encontra-se a diminuição do número de consultas, pois utiliza-se o próprio planejamento de instalação virtual para a confecção do aparelho, ou seja, no mesmo dia o ortodontista já instala o aparelho e os DATs (DE GABRIELE *et al*, 2019; PASQUA e CARDOSO 2021, ANDRE 2023). Além disso, o planejamento guiado proporciona a instalação guiada dos DATs de forma que eles tenham um posicionamento bicortical (LOMBARDO *et al*, 2019; PASQUA *et al*, 2021), o que tem sido considerado como parâmetro essencial para o sucesso da técnica MARPE (LI *et al*., 2020; LEE *et al*., 2021), além de ser de grande importância também para os DATs do Hyrax híbrido. Não obstante, a instalação guiada demonstrou ser fidedigna ao planejamento digital (CASSETTA *et al*, 2018). Além disso, quando a instalação virtual de DATs ocorre no processo alveolar, é possível realizar um posicionamento tricortical, que permite a mesma qualidade de expansão, porém com menor stress e proporcionando uma abertura mais paralela da sutura (BRUCCULERI *et al*., 2024).

Esta técnica permite realizar a instalação virtual em um paciente com idade avançada, estágio avançado de classificação da sutura palatina mediana, assimetria no palato, variação do volume ósseo (MARPE com 6 DATs e corticoperfuração guiada). Mesmo que esteja clara a indicação da técnica, alguns autores afirmam que a técnica de instalação guiada de DATs foi idealizada para auxiliar aquele profissional inexperiente (DE GABRIELE, 2017; WILMES 2019). Em contrapartida, o presente trabalho reforça a necessidade da técnica guiada para prever a trajetória exata do DAT tornando o procedimento mais seguro, eficaz e previsível (MAINO *et al*., 2016; CASSETTA *et al*., 2018; PASQUA e CARDOSO, 2021).

Porém, sabe-se que existem muitas variáveis para o planejamento do MARPE, e consequentemente, muitas possibilidades de customização do dispositivo. Sendo assim, os dispositivos pré-fabricados podem apresentar algumas limitações, principalmente se tratando de casos complexos, uma vez que não são instalados em regiões com volume ósseo adequado devido ao limite entre o canal nasopalatino e a sutura transpalatina. Logo, a utilização de DATs adicionais é uma possibilidade de customização para casos de variação de volume ósseo e canal nasopalatino

aumentado. Considerando que esta possibilidade deve sempre ser considerada durante a instalação virtual. Em outras palavras, a avaliação anatômica, a instalação virtual e o *design* do aparelho devem ser realizados em conjunto, buscando sempre uma resolução segura e efetiva para os pacientes (ANDRÉ *et al*., 2021).

A utilização de anéis adicionais foi realizada com posicionamento bicortical em 100% dos casos, tanto em pacientes do sexo masculino como do sexo feminino. Isso enfatiza dois pontos importantes, que é o planejamento digital somado ao benefício da customização, resultando em um planejamento com maior segurança e previsibilidade. O *design* com DATs adicionais na região anterior da maxila é indicado para aumentar a ancoragem e as chances de sucesso, por garantir mais dois pontos de ancoragem esquelética na região anterior, em uma região com volume ósseo adequado próximo à região de espinha nasal anterior (CURY *et al*, 2019).

Outra vantagem da customização está nos casos de tamanho anteroposterior reduzido da maxila. Nestes casos, utiliza-se anéis esqueléticos na região anterior, seccionando o torno do MARPE e customizando o tamanho do aparelho, resultando em um posicionamento dos DATs anteriores à sutura transpalatina (o que não é possível com o MARPE convencional industrializado). Para casos de aumento do volume do forame nasopalatino, pode-se angular ou afastar estes DATs extras, evitando a colisão com esta estrutura como citado anteriormente.

Os anéis esqueléticos também podem ser usados em processo alveolar quando há espessura óssea reduzida na região paramediana, em sua maioria na região posterior. Porém, em casos com falta de espaço, dentes inclusos, lesões ou outras variáveis anatômicas, é necessário que os DATs anteriores também sejam instalados em processo alveolar. A escolha do local de instalação destes DATs é complexa, pois é necessário se evitar a colisão com as raízes dos dentes e com a artéria palatina maior, e, simultaneamente, ter cuidado com o eixo de inserção dos DATs. Um fator muito importante durante a cirurgia virtual é a simulação dos instrumentais reais em forma virtual (chaves de instalação do MARPE), para saber da possibilidade da instalação em boca (avaliação dos eixos de inserção) sem colisões com os dentes. Este fator somado à região posterior em processo alveolar, que tem uma discrepância transversal grande, muitas vezes gera a necessidade de uma angulação de inserção para a região anterior, evitando que o contra-ângulo ou

torquímetro colidam com o lado oposto da inserção. Porém, esta angulação para anterior depende do espaço presente entre as raízes.

Em pacientes com extensão alveolar do seio maxilar as chances de utilizarmos os DATs em processo alveolar são reduzidas, devido à espessura óssea extremamente diminuída. Em muitos casos, os pacientes apresentam pouco volume ósseo na região parasutural associado com esta falta de volume ósseo na região de processo alveolar, sendo a instalação virtual e real, um desafio (ANDRÉ *et al*., 2021).

O *design* do aparelho também pode variar de acordo com a quantidade de expansão, dentes de apoio, espessura de tecido mole e duro e variações anatômicas como tórus palatino e aumento do diâmetro do canal incisivo, como enfatizado no primeiro artigo (prevalência de variações anatômicas). Isto remete ao fato de que o aparelho MARPE dever ser customizado para cada paciente.

Mesmo assim, existem casos que são mais complexos para MARPE, como os pacientes que apresentam variações anatômicas com idade superior a 30 anos de idade, e sexo masculino (JESUS *et al*, 2021; JEON *et al*, 2021). Com relação à maturação avançada das suturas circumaxilares, não há evidências que há correlação de sucesso ou insucesso com o estágio de maturação (JESUS *et al*, 2021).

Para estes pacientes utilizamos uma técnica na qual corticoperfurações são realizadas na região da sutura palatina mediana, transpalatina e intermaxilar previamente à expansão maxilar, com o objetivo de fragilizar a sutura palatina mediana e, consequentemente, reduzir a resistência durante a expansão. As corticoperfurações guiadas são realizadas de acordo com a anatomia individual de cada paciente. Em alguns pacientes, é possível que esta sutura se apresente também sinuosa e/ou inclinada em um corte coronal.

No presente estudo observamos que a necessidade de corticoperfurações das suturas para fins de expansão maxilar sem cirurgia é semelhante entre os sexos, e que os pacientes com idade intermediária de 33 anos, estão sendo indicados para o uso da técnica como um recurso adicional a fim de se aumentar as chances de sucesso da técnica MARPE. Sabe-se que em média temos cinco perfurações na sutura palatina mediana, três na sutura intermaxilar e duas na sutura transpalatina. Na sutura palatina mediana, as angulações foram em média de 90° em relação ao

plano palatino, e na sutura intermaxilar 140°. Sabendo da importância das corticoperfurações guiadas, somada aos dados encontrados no presente estudo, novas pesquisas clínicas deverão ser realizadas para confirmar os benefícios desta abordagem complementar.

Por se tratar de uma técnica recente e inovadora, algumas dúvidas surgem durante seu planejamento e execução. Desde o início do planejamento, deve-se ressaltar que as perfurações não estão próximas à área de inserção dos DATs. O osso ao redor dos DATs deve ser preservado para que os mesmos suportem as forças advindas da expansão rápida da maxila (ANDRÉ *et al*, 2021), sem que estes "rasguem" o osso. Além disso entender as possíveis variáveis e limitações são extremamente importantes para o planejamento, considerações que foram ponderadas no último artigo (item 4.3.4).

Além disso, constatou-se que a distância entre as perfurações foi, em média, de 2 mm na sutura palatina mediana. Outro fator importante foi que pacientes do sexo masculino apresentaram maior quantidade de tecido mole na região das perfurações, o que pode estar relacionado com maiores índices de insucesso.

Alguns estudos relataram maiores chances de insucesso em pacientes adultos do sexo masculino, especialmente acima de 25 anos de idade (JESUS *et al*, 2021; JEON *et al*, 2021). Isto pode ser explicado por um maior tamanho da maxila. Porém, não foram encontradas diferenças estatisticamente significativas no número de perfurações, distanciamento e inclinação das corticoperfurações na sutura palatina mediana, sutura transpalatina e intermaxilar. Esses achados destacam a importância de se considerar fatores específicos ao tratar pacientes do sexo masculino, especialmente em relação ao potencial de insucesso e ao planejamento das corticoperfurações.

Além disso, o presente artigo tem uma alta relevância clínica, uma vez que os valores médios encontrados já nos trazem uma estimativa de quantas perfurações iremos realizar nos próximos planejamentos, é claro, tendo em mente que cada paciente terá suas particularidades como tamanho da maxila e variações anatômicas.

No presente trabalho dados importantes acerca diagnóstico, planejamento e técnica do Hyrax híbrido e MARPE foram elucidados. O intuito foi apresentar, baseado

em evidencias científicas, ferramentas ao clínico para que ele conheça a prevalência das variações anatômicas mais comuns, introduzindo a técnica guiada para expansão rápida da maxila associada aos DATs. Além disso, objetivou-se demonstrar diferentes tipos de desenhos de aparelho, frente as variações anatômicas discutidas, e ainda apresentar uma técnica eficiente para casos mais complexos, incluindo a fragilização da sutura palatina mediana, transpalatina e intermaxilar de forma guiada. Dessa forma, o ortodontista terá embasamento para uma tomada de decisão mais consolidada, e atuará de forma mais certeira, deixando todo empirismo para o passado.

Por fim, enfatiza-se que mais estudos clínicos deverão ser realizados para tornar as evidências aqui apresentadas ainda mais embasadas cientificamente.

6 CONCLUSÕES

Ficou evidente que o conhecimento acerca das alterações e variações anatômicas é essencial para a realização dos planejamentos virtuais, tanto para a instalação dos DATs, quanto para o desenho dos aparelhos MARPE e Hyrax híbrido, assim como para as corticoperfurações.

No que diz respeito aos dados apresentados no presente estudo, o sexo masculino apresentou maior prevalência de variações anatômicas, assim como maior quantidade de tecido mole na região das perfurações, o que pode estar relacionado aos maiores índices de insucesso relatados na literatura.

Já os pacientes mais jovens algumas variações foram mais evidentes, tais como o formato em W do palato, maior quantidade de falhas ósseas ao longo da maxila, além de dentes inclusos, supranumerários e em processo de erupção. As evidências encontradas direcionam à necessidade de realizar os planejamentos tridimensionais guiados desde os pacientes mais jovens, a fim de se aumentar as chances de sucesso e a qualidade das terapias de expansão maxilar, com aberturas mais paralelas, especialmente em pacientes que buscam melhoras não só de estética e função mastigatória, mas também respiratória.

Estes planejamentos digitais permitem a realização da técnica MARPE mesmo em pacientes com assimetria do palato, variação do volume ósseo e estágio maturação avançada da sutura palatina mediana. Isto amplia as possibilidades de tratamento, uma vez que os DATs, torno e anéis são planejados de forma individualizada.

Os aparelhos pré-fabricados apresentaram limitações por determinarem distâncias fixas que não acompanham as variações anatômicas, tanto no sentido lateral, que influenciam na localização dos DATs, quanto no sentido anteroposterior, como a distância entre o canal nasopalatino e a sutura transpalatina.

O presente estudo demonstrou que a utilização de anéis adicionais, sejam eles com ou sem rosca interna, quando planejados digitalmente, possibilitam a inserção em maior quantidade de osso devido às possibilidades de customização. Ademais, eles podem evitar a colisão com estruturas importantes devido a sua customização, e

os anéis com tampa e rosca mantem o aparelho afastado do tecido mole, evitando complicações decorrentes de inflamações. Vale ressaltar que foi possível observar que os DATs na região do processo alveolar parecem ser uma opção satisfatória para os pacientes com espessura óssea reduzida na região posterior paramediana.

Nos casos mais complexos onde a ferramenta de corticoperfuração guiada é utilizada, a angulação das perfurações varia de acordo com a região, sendo mais anguladas na região da sutura intermaxilar. Não houve diferença entre os sexos com relação ao planejamento da quantidade, distanciamento e inclinação das corticoperfurações.

O presente trabalho deixa claro que a união do planejamento digital, com o conhecimento anatômico e da construção dos aparelhos, assim como o entendimento das forças geradas sobre o complexo nasomaxilar, é essencial para aumentar as chances de sucesso da técnica. Sendo assim, o hábito de se apegar a fatores isolados como classificação de sutura ou apenas a idade é equívoco. O resultado final na técnica de expansão da maxila associada à ancoragem esquelética é a união de vários fatores detalhados nestes 4 artigos.

REFERÊNCIAS

ANDRÉ, C.B. Análise tomográfica para técnica Marpe. **Revista Clínica de Ortodontia Dental Press**, v.17, n.4, p. 50-53, ago./set. 2018.

ANDRÉ CB. Instalação virtual dos aparelhos: para que serve? **Revista Clínica de Ortodontia Dental Press**, v.18, n.5, p.52-58. 2019.

ANDRÉ CB. Mini-implants in T-zone**,** which are the risks? **Clin Orthod**, v.20, n.5, p.42-50, out./nov. 2021.

ANDRÉ, CRISTIANE B. MARPE Guide: da consolidação à evolução da técnica. **Clinical Orthodontics**, v.19, n.5, 2020.

André, C.B.; PASQUA, B.P.M.; RINO NETO J.; NASCIMENTO, F.D. Surgical Digitally Guided Planning for the Mini-Screw Assisted Rapid Palatal Expansion (MARPE) and Suture Perforation: MARPE Guide . 2. ed. London: IntechOpen, 2022. E-book. DOI: 10.5772/intechopen.100226. Disponível em: http://dx.doi.org/10.5772/intechopen.100226. Acesso em: dia mês ano.
ANDRÉ, CB. Guided surgical digital planning for suture cortical perforation: Cortex Guide. **Clin Orthod**, v.21, n.2, p.74-85. 2022.

ANDRÉ, CB. Skeletal ring: a new resource for complex cases. **Clin Orthod**. 2023: 22.2.

ANGELIERI, F.; CEVIDANES, Lucia H.S.; FRANCHI, L.; GONÇALVES, João R.; BENAVIDES, E.; MCNAMARA JÚNIOR, James A. Midpalatal suture maturation: classification method for individual assessment before rapid maxillary expansion. **Am J Orthod Dentofacial Orthop**., v. 144, n.5, p.759-769, nov. 2013. DOI: 10.1016/j.ajodo.2013.04.022. PMID: 24182592; PMCID: PMC4185298.

ANGELIERI, Fernanda et al. Prediction of rapid maxillary expansion by assessing the maturation of the midpalatal suture on cone beam CT. **Dental press journal of orthodontics**, v.21, n.06, p.115-125, 2016.

ANGELIERI, Fernanda et al. Zygomaticomaxillary suture maturation: A predictor of maxillary protraction? Part I-A classification method. **Orthodontics & craniofacial research**, v.20, n.2, p.85-94, 2017.

ANGELL EC. **Treatment of irregularities of the permanent or adult teeth.** Part 1. **Dent Cosmos**, v.1, p.540-541,1860.

BARBOSA, Natália Maria Vieira et al. Reliability and reproducibility of the method of assessment of midpalatal suture maturation: A tomographic study. **The Angle Orthodontist**, v.89, n.1, p.71-77, 2019.

BAYSAL, Asli et al. Evaluation of root resorption following rapid maxillary expansion using cone-beam computed tomography. **The Angle Orthodontist**, v.82, n.3, p.488-494, 2012.

BRUCCULERI L, PELLITTERI F, GIULIANO ASMEP, LOMBARDO ML. Tricortical versus bicortical anchorage in a double-screw Tandem Skeletal Expander and a single-screw Maxillary Anchorage Rapid Palatal Expander: a finite element analysis. **The Korean Journal of Orthodontics**. 2024.

BRUNETTO, Daniel Paludo et al. Mini-implant assisted rapid palatal expansion (MARPE) effects on adult obstructive sleep apnea (OSA) and quality of life: a multi-center prospective controlled trial. **Progress in Orthodontics**, v.23, n.1, p.3, 2022.

BRUNETTO, Daniel Paludo et al. Non-surgical treatment of transverse deficiency in adults using Microimplant-assisted Rapid Palatal Expansion (MARPE). **Dental press journal of orthodontics**, v.22, p.110-125, 2017.

BUCK, Lloyd M. et al. Volumetric upper airway changes after rapid maxillary expansion: a systematic review and meta-analysis. **European journal of orthodontics**, v.39, n.5, p.463-473, 2017.

BUD, Eugen Silviu et al. Observational study regarding possible side effects of miniscrew-assisted rapid palatal expander (MARPE) with or without the use of corticopuncture therapy. **Biology**, v.10, n.3, p.187, 2021.

CANTARELLA, Daniele et al. A new methodology for the digital planning of micro-implant-supported maxillary skeletal expansion. **Medical Devices: Evidence and Research,** p.93-106, 2020.

CASSETTA, M. et al. Palatal orthodontic miniscrew insertion using a CAD-CAM surgical guide: description of a technique. **International Journal of Oral and Maxillofacial Surgery**, v.47, n.9, p.1195-1198, 2018.

CELENK-KOCA, Tugce et al. Evaluation of miniscrew-supported rapid maxillary expansion in adolescents: a prospective randomized clinical trial. **The Angle Orthodontist**, v.88, n.6, p.702-709, 2018.

CHEUNG, Gordon C. et al. The upper airway volume effects produced by Hyrax, Hybrid-Hyrax, and Keles keyless expanders: a single-centre randomized controlled trial. **European journal of orthodontics**, v.43, n.3, p.254-264, 2021.

CHOI, Eun-Hack Andrew et al. Skeletal and dentoalveolar effects of miniscrew-assisted rapid palatal expansion based on the length of the miniscrew: a randomized clinical trial. **The Angle Orthodontist**, v.93, n.4, p.390-397, 2023.

CHOI, Sung-Hwan et al. Nonsurgical miniscrew-assisted rapid maxillary expansion results in acceptable stability in young adults. **The Angle Orthodontist**, v.86, n.5, p.713-720, 2016.

COLAK, Ozge et al. Tomographic assessment of palatal suture opening pattern and pterygopalatine suture disarticulation in the axial plane after midfacial skeletal expansion. **Progress in Orthodontics**, v.21, p.1-9, 2020.

COMPADRETTI, Giacomo Ceroni; TASCA, Ignazio; BONETTI, Giulio Alessandri. Nasal airway measurements in children treated by rapid maxillary expansion. **American journal of rhinology**, v.20, n.4, p.385-393, 2006.

CURY, Sérgio Elias Neves et al. Protocolo diferencial para a técnica MARPE em pacientes com variação no volume ósseo do palato. **Revista Clínica de Ortodontia Dental Press**, v.18, n.4, 2019.

DE GABRIELE, Oronzo et al. The easy driver for placement of palatal mini-implants and a maxillary expander in a single appointment. **J Clin Orthod**, v.51, n.11, p.728-737, 2017.

DINDAROĞLU, Furkan; DOĞAN, Servet. Root resorption in orthodontics. **Turkish Journal of Orthodontics**, v.29, n.4, p.103, 2016.

ERVERDI, Nejat et al. A comparison of two different rapid palatalexpansion techniques from the point of root resorption. **American Journal of Orthodontics and Dentofacial Orthopedics**, v.106, n.1, p.47-51, 1994.

GARIB, Daniela G. et al. Rapid maxillary expansion—tooth tissue-borne versus tooth-borne expanders: a computed tomography evaluation of dentoskeletal effects. **The Angle Orthodontist**, v.75, n.4, p.548-557, 2005.

TOKLU, Miray Gunyuz; GERMEC-CAKAN, Derya; TOZLU, Murat. Periodontal, dentoalveolar, and skeletal effects of tooth-borne and tooth-bone-borne expansion appliances. **American journal of orthodontics and dentofacial orthopedics**, v.148, n.1, p.97-109, 2015.

HAAS, Andrew J. The treatment of maxillary deficiency by opening the midpalatal suture. **The Angle Orthodontist**, v.35, n.3, p.200-217, 1965.

HAAS, A. J. Long-term posttreatment evaluation of rapid palatal expansion. The **Angle Orthodontist**, v.50, n.3, p.189-217, 1980.

INCHINGOLO, Alessio Danilo et al. Rapid Maxillary Expansion on the Adolescent Patient: Systematic Review and Case Report. **Children**, v.9, n.7, p.1046, 2022.

IWASAKI, Tomonori et al. The effect of rapid maxillary expansion on pharyngeal airway pressure during inspiration evaluated using computational fluid dynamics. **International journal of pediatric otorhinolaryngology**, v.78, n.8, p.1258-1264, 2014.

JANG, Hong-Ik et al. Relationship between maturation indices and morphology of the midpalatal suture obtained using cone-beam computed tomography images. **The korean journal of orthodontics**, v.46, n.6, p.345-355, 2016.

JARA, Sebastian M. et al. Posterior Palatal Expansion via Subnasal Endoscopy (2PENN) for Maxillary Deficiency: A Pilot Study. **The Laryngoscope**, v.134, n.4, p.1970-1977, 2024.

JEON, Ji Yoon et al. The success and effectiveness of miniscrew-assisted rapid palatal expansion are age-and sex-dependent. **Clinical oral investigations**, v.26, n.3, p.2993-3003, 2022.

JESUS, AS de et al. Nasomaxillary effects of miniscrew-assisted rapid palatal expansion and two surgically assisted rapid palatal expansion approaches. **International journal of oral and maxillofacial surgery**, v.50, n.8, p.1059-1068, 2021.

KAPETANOVIĆ, Aldin et al. Efficacy of Miniscrew-Assisted Rapid Palatal Expansion (MARPE) in late adolescents and adults with the Dutch Maxillary Expansion Device: a prospective clinical cohort study. **Clinical Oral Investigations**, v.26, n.10, p.6253-6263, 2022.

LEE, Dong-Wook et al. Effects of bicortical anchorage on pterygopalatine suture opening with microimplant-assisted maxillary skeletal expansion. **American Journal of Orthodontics and Dentofacial Orthopedics**, v.159, n.4, p.502-511, 2021.

LEE, Kee-Joon et al. Miniscrew-assisted nonsurgical palatal expansion before orthognathic surgery for a patient with severe mandibular prognathism. **American Journal of Orthodontics and Dentofacial Orthopedics**, v.137, n.6, p.830-839, 2010.

LI, Na et al. Skeletal effects of monocortical and bicortical mini-implant anchorage on maxillary expansion using cone-beam computed tomography in young adults. **American Journal of Orthodontics and Dentofacial Orthopedics**, v.157, n.5, p.651-661, 2020.

LIU, Cuiyu et al. The short-and long-term changes of upper airway and alar in nongrowing patients treated with Mini-Implant Assisted Rapid Palatal Expansion (MARPE): a systematic review and meta-analysis. **BMC oral health**, v.23, n.1, p.820, 2023.

LO GIUDICE, Antonino et al. Description of a digital work-flow for CBCT-guided construction of micro-implant supported maxillary skeletal expander. **Materials**, v.13, n.8, p.1815, 2020.

LOMBARDO, Luca et al. Class II treatment by palatal miniscrew-system appliance: A case report. **The Angle Orthodontist**, v.90, n.2, p.305-313, 2020.

LUZ, Camila Novais et al. Cervical vertebrae maturation assessment as a predictive method for midpalatal suture maturation stages in 11-to 14-year-olds: retrospective study. **Clinical and Investigative Orthodontics**, v.81, n.1, p.43-49, 2022.

MAINO, B. Giuliano et al. A three-dimensional digital insertion guide for palatal miniscrew placement. **J Clin Orthod**, v.50, n.1, p.12-22, 2016.

MEIRELLES, Carolina Marques et al. Analysis of factors associated with the success of microimplant-assisted rapid palatal expansion. **American Journal of Orthodontics and Dentofacial Orthopedics**, v.164, n.1, p.67-77, 2023.

MINERVINO, Bruno L. et al. MARPE guide: a case report. **The Journal of Contemporary Dental Practice**, v.20, n.9, p.1102-1107, 2019.

NAVEDA, Rodrigo et al. Immediate dentoskeletal and periodontal effects of miniscrew-assisted rapid palatal expansion: comparison between young vs middle-aged adults. **American Journal of Orthodontics and Dentofacial Orthopedics**, v.164, n.3, p.416-422, 2023.

NIE, Xiuping et al. Evaluation of palate-related factors of the effectiveness of microimplant-assisted rapid palatal expansion in late adolescents and adults. **Clinical Oral Investigations**, v.27, n.7, p.3531-3544, 2023.

NOJIMA, Lincoln Issamu et al. Mini-implant selection protocol applied to MARPE. **Dental press journal of orthodontics**, v.23, n.05, p.93-101, 2018.

ODENRICK, L.; LILJA, E.; LINDBÄCK, K. F. Root surface resorption in two cases of rapid maxillary expansion. **British Journal of Orthodontics**, v.9, n.1, p.37-40, 1982.

PASQUA, Bruno de Paula Machado et al. Dentoskeletal changes due to rapid maxillary expansion in growing patients with tooth-borne and tooth-bone-borne expanders: A randomized clinical trial. **Orthodontics & craniofacial research**, v.25, n.4, p.476-484, 2022.

PASQUA BPM, CARDOSO M. Planejamento digital guiado na confecção do Hyrax híbrido. Conectando ideias. **Rev. Ortodontia SPO**. 2021.

PROFFIT WR, FIELDS HW, SARVER DM. **Contemporary Orthodontics.** St. Louis: Mosby; 2007. Chapter 6, Grade 4 Severe Need Treatment; p.225 e226. 2007.

STORTO, Camilla Juliana et al. Assessment of respiratory muscle strength and airflow before and after microimplant-assisted rapid palatal expansion. **The Angle Orthodontist**, v.89, n.5, p.713-720, 2019.

SUZUKI, Selly Sayuri et al. Effects of corticopuncture (CP) and low-level laser therapy (LLLT) on the rate of tooth movement and root resorption in rats using micro-CT evaluation. **Lasers in medical science**, v.33, p.811-821, 2018.

WERTZ, Robert A. Skeletal and dental changes accompanying rapid midpalatal suture opening. **American journal of orthodontics**, v.58, n.1, p.41-66, 1970.

WILMES, B.; BOWMAN, J.S.; BAUMGAERTEL, S. Fields of application of mini-implants. *In*: LUDWIG, B.; BAUMGAERTEL, S.; BOWMAN, J.S. (ed.). **Mini-Implants**

in Orthodontics: Innovative Anchorage Concepts. 1. ed. London: Quintessence Publishing Co Ltd, 2008. p.134-157.

WILMES, Benedict et al. The T-zone: median vs. paramedian insertion of palatal mini-implants. **J Clin Orthod**, v.50, n.9, p.543-551, 2016.

WILMES, Benedict et al. Application and effectiveness of a mini-implant-and tooth-borne rapid palatal expansion device: the hybrid hyrax. **World J Orthod**, v.11, n.4, p.323-330, 2010.

WILMES, Benedict; VASUDAVAN, Sivabalan; DRESCHER, Dieter. CAD-CAM–fabricated mini-implant insertion guides for the delivery of a distalization appliance in a single appointment. **American Journal of Orthodontics and Dentofacial Orthopedics**, v.156, n.1, p.148-156, 2019.

ZHAO, Ying et al. Oropharyngeal airway changes after rapid palatal expansion evaluated with cone-beam computed tomography. **American Journal of Orthodontics and Dentofacial Orthopedics**, v.137, n.4, p.S71-S78, 2010.

ZONG, Chen et al. Skeletal and dentoalveolar changes in the transverse dimension using microimplant-assisted rapid palatal expansion (MARPE) appliances. In: **Seminars in Orthodontics**. WB Saunders, 2019. p.46-59.